

Clinical Image

Small Bowel Obstruction Due to Infraumbilical Hernia

Vikas Bhatia MD*, DNB, DM, Lokesh Singh MD*, Jyoti Gupta MD, Uma Debi MD

Department of Radio diagnosis, PGIMER Chandigarh, India

***Corresponding Author:** Dr. Vikas Bhatia, Department of Radio diagnosis, PGIMER Chandigarh, India, Tel: 0091-172-2756381; Fax: 0091-172-2745768; E-mail: drvikasbhatia@gmail.com

Received: 14 March 2020; **Accepted:** 02 April 2020; **Published:** 09 April 2020

Citation: Vikas Bhatia MD, DNB, DM, Lokesh Singh MD, Jyoti Gupta MD, Uma Debi M. Small Bowel Obstruction Due to Infraumbilical Hernia. Journal of Radiology and Clinical Imaging 3 (2020): 048-049.

Keywords: Small bowel obstruction; Infraumbilical; Computed tomography

1. Clinical Image

A 68 year old obese female patient presented to emergency department with a hard palpable lump in periumbilical region for last 7 days. She complains of recurrent vomiting with constipation and obstipation for last three days. Clinical examination revealed an approximately 5 × 8 cms sized, firm, smooth margined, nontender, non yielding mass in infraumbilical region (arrow; Figure 1A) which does not reduce on pressing. No gurgling sound heard on auscultation. Contrast enhanced CT scan revealed presence of an approximately 2.6 cms sized ventral defect in abdominal wall in left para median infraumbilical location through which small bowel (distal jejunal loop), omental fat and properitoneal fat

herniated out into a sac measuring 5 × 7 × 9 cms in AP × TR × CC dimensions (arrow; Figure 1B). There was twisting of bowel loop at neck of sac and proximal dilatation of duodenojejunal loops. Mild mural thickening was seen herniated bowel loop with adjacent fat stranding. No fluid collection within the sac. Distal bowel loops were predominantly collapsed. Radiological impression of a ventral incarcerated hernia with proximal small bowel obstruction was made. Abdominal wall hernias are commonly complicated by strangulation or incarceration. Early diagnosis of these complications is important to ensure early management. Multi-detector row computed tomography (CT) is particularly useful for the evaluation of these hernias and associated complications due to its multiplanar capabilities [1, 2].

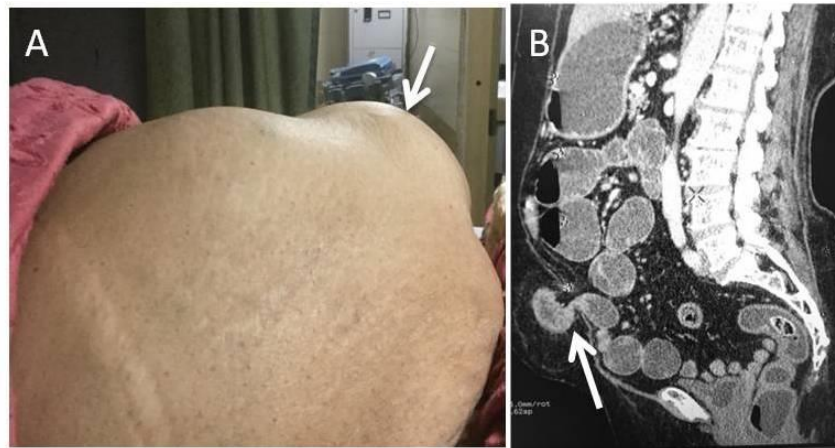


Figure 1A: Hard palpable lump in infraumbilical region.

Figure 1B: Ventral defect in abdominal wall in left para median infraumbilical location through which small bowel (distal jejunal loop), omental fat and properitoneal fat herniated out into a sac.

Patient Consent

Informed consent was taken from the patient

Conflicts of Interest and Funding

Nil

References

1. Aguirre DA, Casola G, Sirlin C. Abdominal wall hernias: MDCT findings. *AJR Am J Roentgenol* 183 (2004): 681-690.
2. Zalcman M, Sy M, Donckier V, et al. Helical CT signs in the diagnosis of intestinal ischemia in small-bowel obstruction. *AJR Am J Roentgenol* 175 (2000): 1601-1607.



This article is an open access article distributed under the terms and conditions of the [Creative Commons Attribution \(CC-BY\) license 4.0](https://creativecommons.org/licenses/by/4.0/)