

## Research Article

# Effectiveness of Topical 100% Trichloroacetic Acid in Treatment of Anogenital Warts in Male Patients

Abdul Qayum, Mohammad Majid Paracha\*, Farah Sagheer

Department of Dermatology, Lady Reading Hospital Peshawar, KPK, Pakistan

**\*Corresponding author:** Mohammad Majid Paracha, Department of Dermatology, Lady Reading Hospital Peshawar, KPK, Pakistan.

**Received:** 31 January 2022; **Accepted:** 07 February 2022; **Published:** 11 February 2022

**Citation:** Abdul Qayum, Mohammad Majid Paracha, Farah Sagheer. Effectiveness of Topical 100% Trichloroacetic Acid in Treatment of Anogenital Warts in Male Patients. Fortune Journal of Health Sciences 5 (2022): 37-42.

### Abstract

**Introduction:** Anogenital warts are benign proliferation of skin and mucosa that result from different types of human papilloma viruses (HPV<sub>s</sub>). Treatment of AGW is aimed at relieving the patient physical and psychological discomfort and preventing the spread of infection by autoinoculation. There is evidence that localized topical application of trichloroacetic acid (100 %) is effective against AGW but due to differences in skin types and possible differences in papilloma virus's types, it was necessary to confirm its effectiveness in Pakistani Population.

**Objectives:** The objective of this study was to ascertain the effectiveness of topical 100 %

Trichloroacetic acid in the treatment of anogenital warts on male external genitalia.

**Methodology:** This descriptive case series study involved 90 cases having AGW (5-20 lesions) on clinical examination. Written informed consent was taken from all patients. Patients were followed at the end of 6 months after completion of treatment and recurrence of AGW was noted.

**Results:** The mean age of the patients was 29.82±7.56 years and all the patients included in study were male. 74 patients out of 90 showed complete clearance of anogenital warts at end of 6 months of treatment however 16 patients out of 90

had recurrence. Hence topical trichloroacetic acid is effective in 82.2% of studied patients.

**Conclusion:** Topical trichloroacetic acid (100%) is an effective treatment of anogenital warts on male external genitalia with complete cure in 82.2% patients at the end of 6 months of treatment.

**Keywords:** Anogenital warts, Human Papillomavirus, Trichloroacetic acid.

## 1. Introduction

Viral warts (verrucae) results from benign proliferation of skin and mucosa caused by infection of different types of human papilloma viruses (HPV<sub>s</sub>). Human Papilloma viruses (HPV<sub>s</sub>) are members of genus family Papovaviruses which are double stranded DNA viruses and replicate inside the nucleus of cells [1]. To date at least 189 HPV<sub>s</sub> genotypes have been described [2]. Though more common in children and adolescents, warts can occur at any age [3]. Some studies report that up to 10% of young population has warts [4]. They may regress spontaneously or increase in number and size according to the immune status of the patient. Cell immunity is very important and warts are particularly exuberant in patients with low immunity as in Hodgkin's disease, AIDS and also in patients taking immunosuppressive agents [3]. Warts may spread directly via person to person contact or indirectly by fomites [5]. Incubation period is variable ranging from few weeks to more than one year. Various types of warts are, common warts (verruca vulgaris), filliform, plantar- as a mosaic type, periungual, flat, genital and oral [3]. Warts may be painful depending on their location [6]. They can affect patients' quality

of life by causing adverse psychological affects or negative social perception [2].

Anogenital warts are extremely common in sexually active adults. Not all infections result in manifestation of AGWs. Annual incidence is 1-2% in sexually active population accounting for almost 3-6 million people worldwide [7]. AGW are not themselves cancerous but warts caused by high-risk types of HPV are predisposed to oncogenic transformation. All female patients with AGW should be considered at risk for cervical, vaginal and vulval dysplasia which can lead to cancer and death [7].

Treatment of warts is aimed at relieving the patient physical and psychological discomfort and preventing the spread of infection by autoinoculation [8]. Numerous modalities have been used to treat warts, such as electro coagulation, liquid nitrogen, hot nitric acid, flexible colloid, intralesional bleomycin, fluorouracil, intralesional interferon, photodynamic and many others but none are uniformly effective and treatment often includes destructive measures, which carry a risk of scarring and are painful [3, 9, 10].

TCA is a well-established peeling agent which is being used for superficial and medium depth peels in treating melasma, acne scarring and wrinkles. Depth of peeling varies according to concentration of TCA [11]. TCA is a self-neutralizing chemical so it does not get absorbed into blood circulation hence higher concentrations can be safely used without any systemic effects [12]. In treatment of AGW TCA can be used as a caustic agent which causes chemical cauterization of AGW when used at higher strengths [13].

In a study conducted in Ankara Turkey in department of obstetrics and gynecology, Gazi university by Zeki M, Tanner MD, Catagay T et al 51 female patients with AGW were included which were treated with topical localized application of 85% TCA after every 5 days for maximum 6 visits or complete clearance of AGW whichever occurred first. None of the patients had recurrence at sixth month follow up. In another study conducted by Abdullah AN, Walzman M, Wade A TCA showed complete clearance of anogenital warts by 70-80% and recurrence rates of 36%. Due to differences in skin types and possible differences in papilloma viruses' types there might be differences in response to TCA in our population. However, in Pakistan no concrete data is available in this regard. So, this study is planned to find out the effectiveness of topical 100 %TCA in treatment of AGW on male external genitalia. Topical TCA is associated with high success rates and low morbidity if sufficient care is taken during application. If proved effective then it will be a useful addition to therapeutic option in the treatment of AGW in our routine practice.

## 2. Materials and Methods

This quasi-experimental study was conducted in Department of Dermatology, Lady Reading Hospital Peshawar from July 2020 to July 2021 over a period of one year. Data was collected by non-probability purposive sampling. The sample size calculation was done by WHO sample size calculation formula. Male patients, age between 18-50 years with a clinical diagnosis of anogenital warts, having 5-20 warts of size less than 2cm were included in the study. Patients who have received other treatments for anogenital warts, hypersensitive to trichloroacetic acid and patients on cytotoxic or immunosuppressive

therapy were excluded from the study. Written informed consent was taken from all patients before initiation of therapy. Liquid paraffin was applied to surrounding area of anogenital warts to avoid spillage on surrounding skin. 100% trichloroacetic acid was topically applied to anogenital warts with cotton bud. Anogenital warts were then monitored carefully until a frost appears. Patients were asked to wash the area with water. If spillage occurs it's going to be neutralized by bicarbonate solution. Procedure was repeated after every 5 days for maximum of 6 cycles or till complete clearance of anogenital warts whichever occurs first. Effectiveness was assessed at 6 months after last session and was going to be considered effective if complete clearance occurs without recurrence. All data was entered on a predesigned proforma. Analysis of results was made using SPSS version 20. Mean  $\pm$  standard deviation was calculated for continuous variable like age. Frequencies and percentages were calculated for all the categorical variables like effectiveness.

## 3. Results

90 patients were included in this quasi-experimental study. The age of the patients ranged from 19 year to 48 years with a mean of  $29.82 \pm 7.56$  years as shown in table.

All the patients included in the study were males. Before starting treatment, the number of lesions ranged from a minimum of 4 to maximum of 19 with a mean of  $13.69 \pm 3.87$  lesions as shown in table. On second visit the number of maximum lesions were 18 and minimum was zero with a mean of  $8.73 \pm 4.07$ . On third visit maximum number of lesions were 12 and minimum was zero with a mean of  $5.60 \pm 3.42$ . On fourth visit maximum number of lesions 10 and

minimum was zero with a mean of 2.98±2.60. On fifth visit maximum number of lesions were 6 and minimum was zero with a mean of 1.31±1.71. On sixth visit number of maximum lesions were 3 and minimum was zero with a mean of 0.44±0.79.

As per operational definition all the patients were assessed at 6 months after the last visit and if there was no recurrence then the treatment was considered effective otherwise ineffective. At the end of 6 months treatment is effective in 74 patients out of 90 which is 82.2% and ineffective in 16 out of 90 patients which is 17.8% as shown in table.

Age of study participants

	Mean	SD	Minimum	Maximum
Age	29.82	7.56	19.00	48.00

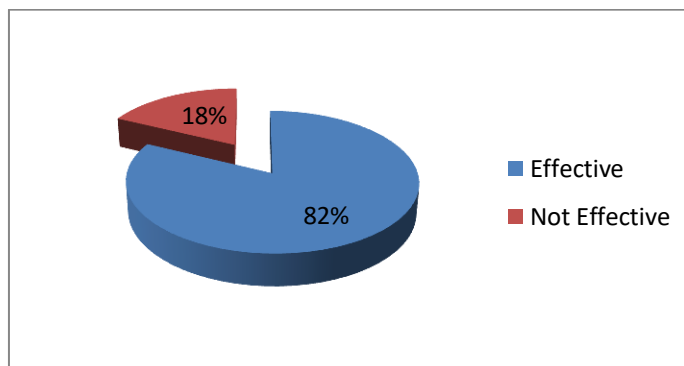
Number of lesions on each visit

No. of Visits	Mean	SD	Minimum number of lesions	Maximum number of lesions
1	13.69	3.87	4.00	19.00
2	8.73	4.07	0.00	18.00
3	5.60	3.42	0.00	12.00
4	2.98	2.60	0.00	10.00
5	1.31	1.71	0.00	6.00
6	.44	.79	0.00	3.00

Outcome of 100% Trichloroacetic acid on anogenital warts on male external genitalia

Treatment	N	%
Effective	74	82.2%
Not Effective	16	17.8%

Pie chart representation of outcome of topical 100% trichloroacetic acid in treatment of anogenital warts on male external genitalia



#### 4. Discussion

Genital human papillomavirus infection is the most common sexually transmitted disease. Each year 1 million new patients are diagnosed to have anogenital warts out of which two third are women. Treatment of anogenital warts is aimed to relieve patient of the physical and psychological discomfort. Numerous treatment options are available for treating anogenital warts. Various ablative and non-ablative modalities like surgical excision, cryotherapy, electrocautery, carbon dioxide laser, imiquimod, podophyllin, podophyllotoxin and interferons are being used for treating anogenital warts with variable results [7].

Trichloroacetic acid is a caustic agent causing chemical cauterization of anogenital warts [13]. It induces protein precipitation and coagulation necrosis of cell in epidermis and necrosis of collagen in papillary to upper dermis layer. Necrotic layers slough off over several days and skin re-epithelizes from adnexal collagen.<sup>12</sup> Trichloroacetic acid erodes skin and mucous membrane but generally is not absorbed systemically [7]. This treatment appears to have best safety profile in treating anogenital warts in pregnancy [7].

Abdullah AN, Walzman M and Wade A in 1993 conducted a study on anogenital warts in which they compared the results of liquid nitrogen (cryotherapy) and topical trichloroacetic acid on 43 patients and documented 70% clearance rates of anogenital warts with 36% recurrence rate with TCA [14]. Schwart DB et al conducted a study in 1988 comparing the results of trichloroacetic acid and laser in treating anogenital warts in pregnant females and documented 97% clearance rate by trichloroacetic acid [15].

In a study conducted by Taner ZM et al in 2007 for assessing outcome of trichloroacetic acid in treating anogenital warts 51 patients were studied and documented 100% clearance at 6 months of ending treatment [13]. The present study was aimed at confirming the outcome of topical 100% trichloroacetic acid in local population where the response may have differed due to differences in skin types and papilloma virus's subtypes. The mean age of the patients in our study was  $29.82 \pm 7.56$  years. All the included patients were males. Our results agree with those of Taner ZM et al showing 82.2% clearance rates of anogenital warts.

Results of our study thus confirm the efficacy of topical trichloroacetic acid (100%) in treating anogenital warts in Pakistani population. Our study however was limited to the efficacy of treatment and we didn't consider the side effects, which is an important aspect of treatment and should be considered in future studies.

#### 5. Conclusion

Topical Trichloroacetic acid (100%) solution is an effective treatment of anogenital warts on male external genitalia with complete cure in 82.2% patients at the end of 6 months of treatment.

#### References

1. Sharquie KE, Khorsheed AA, Al-Nuaimy AA. Topical zinc sulphate solution for treatment of viral warts. Saudi Med J 28 (2007): 1418-21.
2. Gaston A, Garry RF. Topical vitamin A treatment of recalcitrant common warts. Virol J 9 (2012): 21.

3. Stefani M, Bottino G, Fontenelle E, Azulay DR. Efficacy comparison between cimetidine and zinc sulphate in the treatment of multiple and recalcitrant warts. *An Bras Dermatol* 84 (2009): 23-9.
4. Choi JW, Cho S, Lee JH. Does immunotherapy of viral warts provide beneficial effects when it is combined with conventional therapy? *Ann Dermatol* 23 (2011): 282-7.
5. Mulehem E, Pinelis S. Treatment of nongenital cutaneous warts. *Am Fam Physician* 84 (2011): 288-93.
6. Bohlooli S, Mohebipoor A, Mohammadi S, Kouhnavard M, Pashapoor S. A Comparative study of fig tree efficacy in the treatment of common warts vs cryotherapy. *Int J Dermatol* 46 (2007): 524-6.
7. Scheinfeld N, Lehman DS. An evidence based review of medical and surgical treatments of genital warts. *Dermatology online journal* (2012): 5.
8. Oglio FD, Amico VD, Nasca MR et al. Treatment of cutaneous warts. *Am J Clin Dermatol* 13 (2011): 73-96.
9. Mun JH, Kim SH, Jung DS, Ko HC, Kim BS, Kwon KS, et al. Oral zinc sulfate treatment for viral warts: an open-label study. *J Dermatol* 38 (2011): 541-5.
10. Khattar JA, Musharrafieh UM, Tamim H, Hamadeh GN. Topical zinc oxide vs. salicylic acid-lactic acid combination in the treatment of warts. *Int J Dermatol* 46 (2007): 427-30.
11. Khunger N. Trichloroacetic acid. Step by step chemical peels. 1<sup>st</sup> ed. New Delhi, India: Jaypee Medical Publishers (2009): 90-110.
12. Bharadwaj D, Khunger N. An assessment of the efficacy and safety of CROSS technique with 100% TCA in management of ice pick acne scars. *J Cutan Aesthet Surg* 3 (2010): 93-96.
13. Zeki M, Tanner MD, Cagatay T, et al. Therapeutic value of TCA in treatments of isolated genital warts on external female genitalia. *The Journal of Reproductive Medicine* 52 (2007): 521-525.
14. Abdullah AN, Walzman M, Wade A. Treatment of external genital warts comparing cryotherapy (liquid nitrogen) and trichloroacetic acid. *Sex Transm Dis* 20 (1999): 344-45.
15. Schwart DB, Greenberg MD, Daoud Y et al. Genital condylomas in pregnancy: use of trichloroacetic acid and laser therapy. *Am J Obstet Gynecol* 158 (1988): 1407-16.



This article is an open access article distributed under the terms and conditions of the [Creative Commons Attribution \(CC-BY\) license 4.0](https://creativecommons.org/licenses/by/4.0/)