

Research Article

Assessment of Valvular Dysfunction and Aortopathy Involvement in Patients with Bicuspid Aortic Valve: Echocardiographic Study

Saousan SERBOUT*, Anass MAAROUFI, Hatim ZAHIDI and Rachida Habbal

Department of Cardiology, Ibn Rochd University Hospital, Casablanca, Morocco

***Corresponding author:** Saousan SERBOUT, Department of Cardiology, Ibn Rochd University Hospital, Casablanca, Morocco, E-mail: saousan90@gmail.com

Received: 01 March 2020; **Accepted:** 16 March 2020; **Published:** 20 March 2020

Citation: Saousan SERBOUT, Anass MAAROUFI, Hatim ZAHIDI and Rachida Habbal. Assessment of Valvular Dysfunction and Aortopathy Involvement in Patients with Bicuspid Aortic Valve : Echocardiographic Study. Cardiology and Cardiovascular Medicine 4 (2020): 087-096.

Abstract

Bicuspid aortic valve is relatively common congenital cardiac anomaly, it is found in approximately 0,5-2% of the general population, which 75% of them are male. Was first described by Vinci Leonard and is defined by the presence of two abnormal leaflets, usually unequal in size, and not three aortic normal leaflets (as in the normal tricuspid valve).

A prospective single center study had been performed in the department of Cardiology, Ibn rushd university hospital, to assess the evolution of valvular and aortic diameter in adults patients with bicuspid aortic valve. A total of 106 patients with bicuspid aortic valve were included during a follow up of 10 years. Aortic dimensions and other echocardiographic parameters were obtained from the echocardiography database of department. Patients with bicuspid aortic valve were

mainly male (76,4%), with a mean age of 49 +/- 15 years and a significant proportion of hypertensive patients (50.9%).

We notice a majoration of the number of patients with aortic stenosis over time ($p < 0,001$), with an involvement of transthoracic echocardiography parameters of aortic stenosis, a decrease of the aortic valve area, indexed or not, an increase of peak velocity and mean gradient, this progression was significantly higher ($p = 0.0025$) in subjects with aortic stenosis at inclusion: 16cm/s/year against 4.6cm/s/y and an mean gradient of 3.5mmHg/year against 0.6mmHg/y. Whereas the progression of dilatation of sinus of Valsalva and tubular ascending aorta, was also more important in patients with aortic stenosis at inclusion compared with those who had not, aortic diameters between the 1st and the last control, sinus of Valsalva:

0,17- 0,3 mm/year, tubular ascending aorta : 0,32 - 0,6 mm/year. A significant progression of aortic diameter was observed in patients with a small aorta at inclusion compared of others.

This study reinforces the fact that clinical and echographic surveillance of these patients, even if they are asymptomatic, thus fundamental and necessary to better prevent complications.

Keywords: Bicuspid aortic valve; Transthoracic echocardiography; Valvular dysfunction; Aorticopathy

Introduction

Bicuspid aortic valve disease (BAV) is now known to be the most common congenital lesion affecting the human heart, with an estimated prevalence of 0,5% to 2% in the general population [1]. Which 75% of them are male (Dargis et al., 2016; Longobardo et al., 2016) [2,3].

It is suggested that the BAV lesion can cause morbidity and mortality more than any other congenital heart disease [4]. It requires serious follow-up; Most patients with a bicuspid aortic valve will develop some complications during life such as aortic stenosis, aortic regurgitation and aortic dissection [4]. The majority of subjects with bicuspid AV will resort to heart surgery at during their life, mainly for an aortic valve disease, more rarely for a pathology of the ascending aorta, aortic dilatation secondary to a BAV is called bicuspid aorticopathy [5]. The disease represents a heterogeneous spectrum, leading to difficulties in the interpretation of follow-up and treatment options [6]. Transthoracic echocardiography (TTE) is the first-line imaging modality used for the diagnosis and monitoring of patients with BAV. It provides data regarding concomitant aorticopathy and valvular dysfunction.

The aim of this work was to study the progression of the disease (valvular and aortic) in a patients with a BAV followed for a prolonged period of observation.

Methods

Between January 2009 and January 2019, 106 consecutive patients suspected or with a previous diagnosis of BAV were included. All patients were in sinus rhythm. The data collected will be extracted from the medical file.

They were excluded all the patients with a history of aortic or valvular surgery, patients with others pathology causing aorticopathy, antecedents of infectious endocarditis, valvulopathy of other etiology in particular rheumatic, a TTE quality inadequate for diagnosing a BAV (severe calcification of the aortic valve). Patients who refused to participate in the study or who were lost to follow-up were also excluded.

All patients received at least one 1 ETT during follow-up. Echocardiographic studies were carried out using equipment (Philips). The quantification of size and diameter of the heart chambers was determined according to the recommendations of guidelines of the American Society of Echocardiography [7]. The study of the aorta concerned: (1) the aortic valve annulus, (2) the maximal diameter of the sinuses of Valsalva, (3) the sinotubular junction, and averaged at each aortic level, and the results were indexed for body surface area (BSA) (Figure 1).

LV systolic function was assessed with the calculation of the LV ejection fraction using the Simpson biplane method [7].

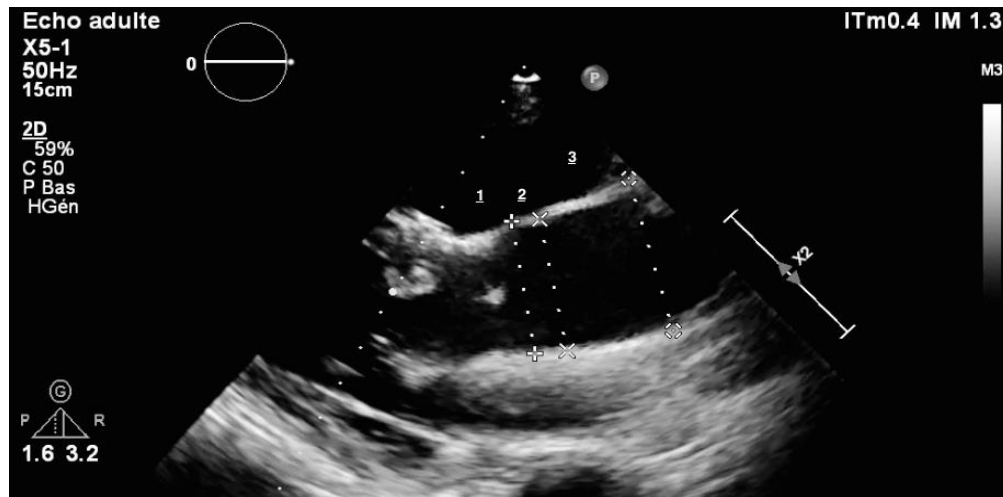


Figure 1: Aortic dimensions : (1) sinus of Valsalva, (2) the sinotubular junction, and (3) the tubular portion of the ascending aorta.

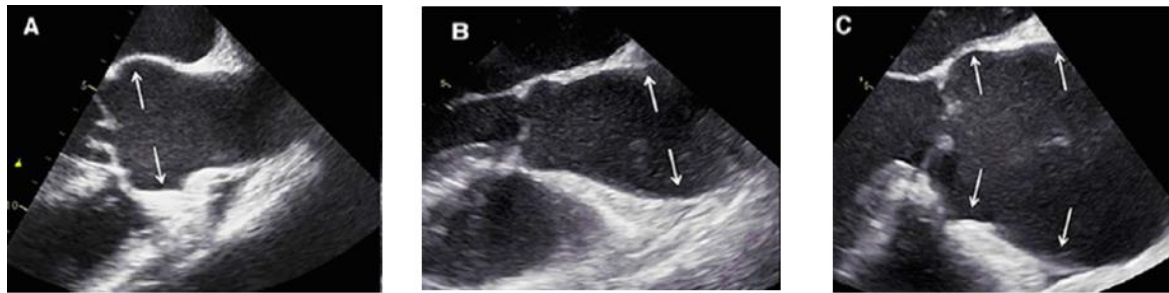
The degree of aortic stenosis (AS) was graded using Doppler echocardiography (five-chamber view, right parasternal). The primary haemodynamic parameters used for clinical evaluation of AS severity was, AS jet velocity, Mean transaortic gradient, Valve area by continuity equation, velocity ratio, Planimetry of anatomic valve area if is possible and acceleration time /ejection time ratio. Severity of AS was graded as mild in patients with a maximum aortic peak velocity (V_{max}) of 2.6 to 2,9 m/second, moderate in those with a V_{max} of 3 to 4m/second and severe in those with a V_{max} of ≥ 4 m/ second to evaluate statistical differences, similar to a previous report [7].

Degree of aortic regurgitation (AR) was defined by a composite evaluation of venae contracta, PISA method, Pressure half-time and Diastolic flow reversal in the descending aorta according to guidelines [8].

The ascending aorta is dilated if its diameter exceeding 39 mm [9] and a sinus of Valsalva with a diameter greater than 40 mm is estimated to be dilated [10]. the measurements were indexed to small body size, and diameter was determinatd to be 22 mm / m^2 and 19 mm / m^2 for sinus of valsalva and for the ascending aorta respectively.

Three different patterns of bicuspid aortic valve aortopathy were defined by Park, [11] based on the tract(s) involved in the dilatation: enlargement of only the Tubular portion of the ascending aorta, enlargement of both the tubular portion and root, and enlargement of only sinus of valsalva (Figure 2).

All analyses were performed using SPSS for Mac, Version 21.0 (SPSS Inc., Chicago, IL, USA).



Type A : SV > 40 mm et TAA < 40 mm **Type B** : TAA > 40 mm et SV < 40 mm **Type C** : SV et TAA > 40 mm
 SV :Sinus of valsalva ; TAA: tubular ascending aorta

Figure 2: Park’s classification of aortopathy : The classification of aortopathy: dilatation of the aortic root (including sinus of Valsalva or sinotubular junction) (A), isolated dilatation of the ascending aorta (B), and diffuse dilatation of the aortic root and ascending aorta (C). The arrows indicate the dilated levels.

Results

Patient characteristics

Table 1 displays the baseline characteristics of the study population.

Patients with bicuspid aortic valve were mainly male (76,4%), the median age of the study group was 49

years (range: 34–64 years). It was a significant proportion of hypertensive patients (50.9%).The frequency of hypertension, diabetes mellitus, dyslipidemia and symptoms is presented in Table 1. In total, 35 (33%) patients had mild AS, and 4 (4 %) had moderate-to-severe AR.

Age (years)	49(34–64)
Male, n (%)	81 (76,4)
Height (cm)	167 ±8,3
Weight (kg)	72±9
Smoking	15 (14.2%)
Arterial hypertension, n (%)	54 (50,4)
Diabetes mellitus, n (%)	36 (34)
Dyslipidemia	23 (21.7%)
CAD	13 (12.3%)
Stroke	12 (11.3%)
NHYA I-II	104 (98.1%)
NYHA III-IV	2 (1.9%)
Aortic stenosis, n (%)	
None	67 (63%)
Mild	35 (33%)
Moderate to severe	4 (4%)

Table 1: Demographic variables and echocardiographic findings in patients with bicuspid aortic valve.

Echocardiography

Aortic diameters at last follow-up echocardiography were 40 ± 0.6 and 41 ± 0.6 mm at sinuses and ascending level, respectively (Table 2).

Variables	1 st echocardiography	Last echocardiography	p
Aortic stenosis (area < 2 cm ²) n° (%)	37 (n = 39)	60 (n = 64)	< 0.001
Aortic valve area (cm ²)	2.3 ± 1.1	1.85 ± 1.1	< 0.001
Indexed aortic valve area (cm ² /m ²)	1.3 ± 0.6	1.1 ± 0.7	< 0.001
Peak velocity (cm/s)	228 ± 90	261 ± 124	< 0.001
Mean gradient (mmHg)	15 ± 12	21 ± 19	< 0.001
Sinus of Valsalva (mm)	38 ± 6	40 ± 6	< 0.001
Tubular ascending aorta (mm)	38 ± 6	41 ± 6	< 0.001

Table 2: TTE parameters progression over time

Whereas the progression of dilatation of sinus of Valsalva and tubular ascending aorta, was also more important in patients with aortic stenosis at inclusion compared with those who had not, aortic diameters between the first and the last control, sinus of Valsalva: 0.17- 0.3 mm/year, tubular ascending aorta : 0.32 – 0.6 mm/year. A significant progression of aortic diameter was observed in patients with a small aorta at inclusion compared of others. (Figure 3).

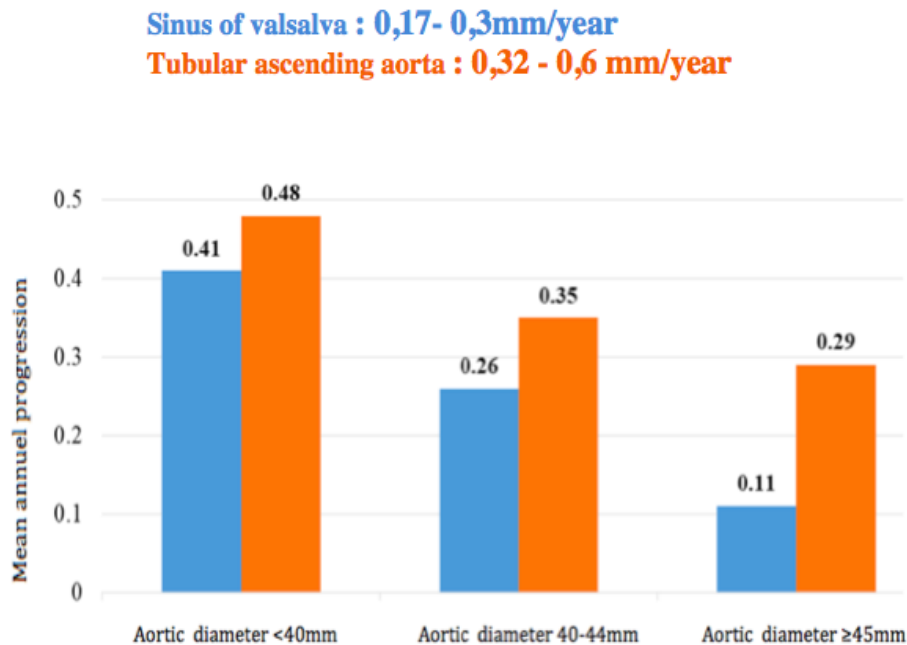


Figure 3: Comparison of the mean annual rate of progression of SV and TAA diameter as a function of aortic diameter at diagnosis of BAV.

The aortic root diameter increased over time in 41% of patients, and the ascending diameter increased in 55%. In 32% of patients, no growth was observed at any level. Also, we notice a majoration of the number of patients with aortic stenosis over time ($p < 0,001$), with an involvement of transthoracic echocardiography parameters of aortic stenosis, a decrease of the aortic valve area, indexed or not, an increase of peak velocity and mean gradient (Table 2). This progression was significantly higher in subjects with aortic stenosis at inclusion: 16cm/s/year against 4.6cm/s/year and an mean gradient of 3.5mmHg/year against 0.6mmHg/year. ($p = 0.0025$) (Table 3).

	Patient without AS at inclusion (n = 67)	Patient with AS at inclusion (n = 39)	p
Peak velocity(cm/s/an)	4.6	16	= 0.0025
Mean Gradient (mmHg/an)	0.6	3.5	< 0.001

Table 3: Aortic stenosis progression

Complications

During follow-up of 10 years, 9 patients with BAV developed infectious endocarditis corresponding to a rate of 8.5%. This complication was higher in men than in women ($P = 0.037$). However, none of the patients underwent aortic dissection or rupture in this series. 48 patients underwent a surgical procedure regardless of whether it was an aortic valve replacement alone or associated with an aortic replacement. All other patients are still under continuous surveillance (Figure 4).

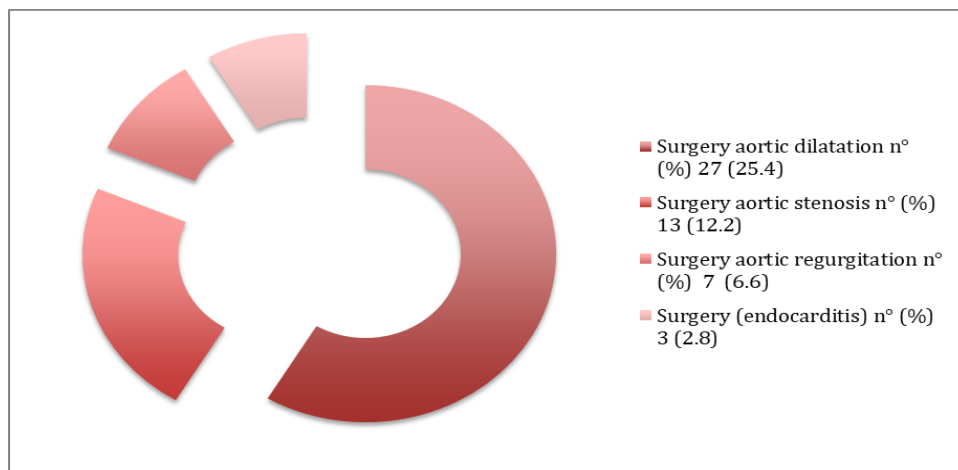


Figure 4: Complications during follow up

Discussion

Like most studies, this work confirm the male predominance of BAV with a male/ female ratio of 3/1 [12], the GenTAC registry presented at the 2015 American Heart Association Scientific Sessions meeting showed that men had more frequently type 1 BAV with fusion between the left and right coronary cusps than women 81.5% versus 69.0%, $P=0.03$), whereas type 1 BAV with fusion between the right and noncoronary cusps was more frequently observed in women (18.5% versus 31.0%, $P=0.03$) [13], but we have non studies that explain sex differences of bicuspid aortic valve morphology and the frequency of male. The exact pathogenesis of the formation of bicuspid aortic valves is not yet fully clear and understood.

Most patients with a bicuspid aortic valve will develop some complication during life, most released studies has been concentrated to evaluate two important complications: aortic dissection and aortic rupture [14,15]. Conversely, Few small study sought to identify risk factors for rapid growth of the ascending aorta in patients with bicuspid aortic valve. It is important to note that dissection can also occur at small aortic diameters.

Earlier surgery has been recommended for patients with aortic diameter increase >2 mm/year [16]. In the present series, mean growth rates fell within the range of previously reported values [17,18]. Thus, even this cutoff might be too high. Although typically progressive in its nature (diameters remained stable over time in only 1/3 of patients), Bicuspid aortic valve aortopathy was generally an indolent disease, with slow mean growth rates. Nevertheless, the mean ascending diameter increase in our fast progression group was 0.6 mm/year and 0.3mm respectively in tubular ascending aorta and sinus of valsalva; therefore, our definition successfully identified patients at higher risk of requiring surgery [14].

As other complication, bicuspid aortic valve was involved in mild to severe AS. TTE has been recommended in bicuspid aortic valve patients with symptoms. It could provide precise diagnosis and severity of AS, abnormal hemodynamic, left ventricle function, left stroke volume, and, TTE might be used to decide the surgical intervention time and speculate prognosis [19]. In our series progression of AS was significant ($p < 0.001$).

Recently, Michelena, et al. [5] suggested that morbidity (including aortic valve and / or ascending thoracic aorta replacement surgeries, the presence of severe AR and / or AS, thoracic aortic aneurysm but also aortic dissections as well as endocarditis) would be more important in man while mortality would be higher in women (HR = 1.22 (95% CI: [1.02-1.45]; $p = 0.026$) and HR = 1.44 (95% CI: [1.15-1.79]; $p = 0.001$)) in the two cohorts analyzed. In our study there were no deaths.

Several studies have raised the hypothesis of the BAV phenotype and its role in the rapid progression of valve dysfunction and especially in the evolution of arterial diameters [20], however, the results in the literature are still ambiguous.

The contradictory results of the studies as well as the low numbers of patients studied [20,21] did not allow the creation of a guideline to suggest carrying out a precise valvular phenotyping of the BAV and to organize follow-up intervals specific for different phenotypes, so the use of TEE for this approach was not specifically recommended, except in certain situations [22].

Conclusion

This study reinforces the fact that clinical and echographic surveillance of these patients, even if they are asymptomatic, thus fundamental and necessary to better prevent complications.

What is already known on this topic

Risk of aortic events for aortic aneurysm in BAV.

What this study adds

Echographic surveillance of patients with bicuspid aortic valve is fundamental to prevent complications even with small aortic diameters.

Competing interests

The authors declare no competing interest.

Funding

We have no funding sources to declare

Authors' contributions

The contributions of authors is as follows :

Design of the study : Serbout, Maaroufi and Zahidi

Aquisition of data : all authors

Analysis and interpretation of data : Serbout, Maaroufi and Habbal

Statistical analysis : Serbout, Maaroufi and zahidi

drafting the work or revising it critically for important intellectual content : all authors.

References

1. Baumgartner H, Bonhoeffer P, De Groot NM, de Haan F, Deanfield JE, et al. ESC Guidelines for the management of grown-up congenital heart disease. *Eur Heart J* 31 (2010): 2915-57.
2. Dargis N, Lamontagne M, Gaudreault N, Sbarra L, Henry C, Pibarot P, Mathieu P, Bossé Y. Identification of Gender-Specific Genetic Variants in Patients With Bicuspid Aortic Valve. *Am J Cardiol* 117 (2016): 420-6.
3. Longobardo L, Jain R, Carej S, Zito C, Khandheria BK. Bicuspid Aortic Valve: Unlocking the Morphogenetic Puzzle. *Am J Med* 129 (2016): 796-805.
4. Ward C. Clinical significance of the bicuspid aortic valve. *Heart* 83 (2000): 81-85.
5. Michelena HI, Della Corte A, Prakash SK, Milewicz DM, Evangelista A, Enriquez-Sarano M. Bicuspid aortic valve aortopathy in adults: Incidence, etiology, and clinical significance. *Int J Cardiol* 201 (2015): 400-7.
6. Fedak PW, Barker AJ, Verma S. Year in review: bicuspid aortopathy. *Curr Opin Cardiol* 31 (2016):132-8.
7. Lang RM, Badano LP, Mor-Avi V, Afilalo J, Armstrong A, et al. Recommendations for cardiac chamber quantification by echocardiography in adults: an update from the American Society of Echocardiography and the European Association of Cardiovascular Imaging. *J Am Soc Echocardiogr* 28 (2015): 1-39.e14
8. Nishimura RA, Otto CM, Bonow RO, Carabello BA, Erwin JP 3rd, et al. 2014 AHA/ACC Guideline for the Management of Patients With Valvular Heart Disease: executive summary: a report of the American College of Cardiology/American Heart Association Task Force on Practice Guidelines. *Circulation* 129 (2014): 2440-92.
9. Della Corte A, Bancone C, Dialetto G, Covino FE, Manduca S, Montibello MV, De Feo M, Buonocore M, Nappi G. The ascending aorta with bicuspid aortic valve: a phenotypic classification with potential prognostic significance. *Eur J Cardiothorac Surg* 46 (2014): 240-7.
10. Kang JW, Song HG, Yang DH, Baek S, Kim DH, et al. Association between bicuspid aortic valve phenotype and patterns of valvular dysfunction and bicuspid aortopathy: comprehensive evaluation using MDCT and

- echocardiography. *JACC Cardiovasc Imaging* 6 (2013): 150-61.
11. Park CB, Greason KL, Suri RM, Michelena HI, Schaff HV, Sundt TM 3rd. Fate of nonreplaced sinuses of Valsalva in bicuspid aortic valve disease. *J Thorac Cardiovasc Surg* 142 (2011): 278-84.
 12. McKellar SH, Michelena HI, Li Z, Schaff HV, Sundt TM 3rd. Long-term risk of aortic events following aortic valve replacement in patients with bicuspid aortic valves. *Am J Cardiol* 106 (2010): 1626-33.
 13. Roman MJ, Pugh NL, Devereux RB, Eagle KA, Holmes K, et al. Aortic Dilatation Associated With Bicuspid Aortic Valve: Relation to Sex, Hemodynamics, and Valve Morphology (the National Heart Lung and Blood Institute-Sponsored National Registry of Genetically Triggered Thoracic Aortic Aneurysms and Cardiovascular Conditions). *Am J Cardiol* 120 (2017): 1171-1175.
 14. Michelena HI, Khanna AD, Mahoney D, Margaryan E, Topilsky Y, Suri RM, Eidem B, Edwards WD, Sundt TM 3rd, Enriquez-Sarano M. Incidence of aortic complications in patients with bicuspid aortic valves. *JAMA* 306 (2011): 1104-12.
 15. Elefteriades JA, Farkas EA. Thoracic aortic aneurysm clinically pertinent controversies and uncertainties. *J Am Coll Cardiol* 55 (2010): 841-57.
 16. Vahanian A, Alfieri O, Andreotti F, Antunes MJ, Barón-Esquivias G, et al. Guidelines on the management of valvular heart disease. *Eur Heart J* 33 (2012): 2451-96.
 17. Thanassoulis G, Yip JW, Filion K, Jamorski M, Webb G, Siu SC, Therrien J. Retrospective study to identify predictors of the presence and rapid progression of aortic dilatation in patients with bicuspid aortic valves. *Nat Clin Pract Cardiovasc Med* 5 (2008): 821-8.
 18. Etz CD, Zoli S, Brenner R, Roder F, Bischoff M, Bodian CA, DiLuozzo G, Griep RB. When to operate on the bicuspid valve patient with a modestly dilated ascending aorta. *Ann Thorac Surg* 90 (2010): 1884-90.
 19. Nishimura RA, Otto CM, Bonow RO, Carabello BA, Erwin JP 3rd, et al. 2017 AHA/ACC Focused Update of the 2014 AHA/ACC Guideline for the Management of Patients With Valvular Heart Disease: A Report of the American College of Cardiology/American Heart Association Task Force on Clinical Practice Guidelines. *Circulation* 135 (2017): e1159-e1195.
 20. Fernandes SM, Khairy P, Sanders SP, Colan SD. Bicuspid aortic valve morphology and interventions in the young. *J Am Coll Cardiol* 49 (2007): 2211-4.
 21. Schaefer BM, Lewin MB, Stout KK, Gill E, Prueitt A, Byers PH, Otto CM. The bicuspid aortic valve: an integrated phenotypic classification of leaflet morphology and aortic root shape. *Heart* 94 (2008): 1634-8.
 22. Erbel R, Aboyans V, Boileau C, Bossone E, Bartolomeo RD, et al. 2014 ESC Guidelines on the diagnosis and treatment of aortic diseases: Document covering acute and chronic aortic diseases of the thoracic and abdominal aorta of the adult. The Task Force for the Diagnosis and Treatment of Aortic Diseases of the European Society of Cardiology (ESC). *Eur Heart J* 35 (2014): 2873-926.



This article is an open access article distributed under the terms and conditions of the [Creative Commons Attribution \(CC-BY\) license 4.0](https://creativecommons.org/licenses/by/4.0/)