


Research Article

Relationship between Maxillary Arch Shape and Maxillary Labial Bone Dimensions: A Pilot Study

Ahmad Assari^{1*}, Shereen Shokry², Dana Fayez Al-Senan³, Tasnim Najed Alsbaih⁴, Mada Awadh Alanazi⁵, Mohammed Ahmed Alostaz⁶

Abstract

Objective: To determine whether there is any relationship between the thickness of the labial alveolar bone wall in the anterior portion of the maxilla and arch shape.

Materials and Methods: Thirty patients (age, 12-53 years) were selected from archived cone beam computed tomography (CBCT) cases. All maxillary front teeth were present in all the cases. The distance between the cemento-enamel junction (CEJ) and the facial bone crest and the thickness of the labial alveolar bone wall at distances of 1, 3, and 5 mm apical to the facial bone crest were measured.

Results: The distance between the CEJ and the facial bone crest ranged from 2.24 mm and 3.08 mm. No significant differences were found between the thickness of the bone wall at 1, 3, and 5 mm apical to the crest. A significant difference was found between the U-shaped arch on one side and the V-shaped and square-shaped arches on the other side. The U-shaped arch and labial bone wall thickness were correlated at the 1-mm distance ($F = (8, 276) = 3.24, p = 0.002$). U-shaped and V-shaped arches were common in women, whereas square-shaped arches were common in men ($\chi^2 = 105.5, p = 0.000$).

Conclusion: Our study is the first to associate arch shape and labial alveolar bone wall thickness.

Clinical relevance: The association between the U-shaped arch and bone wall thickness may constitute a new indicator for the tendency of the labial alveolar bone to resorb after extraction and placement of endo-osseous implants.

Keywords: Anterior teeth; Arch shape; Bone dimensions; Cone beam computed tomography

Introduction

The anterior teeth play an important role in dental and facial esthetics [1]. A previous study showed that some dimensional changes occur in the alveolar process following tooth extraction, where the labial cortical bone was found to resorb first in the labial and alveolar crest directions [2]. The greatest amount of bone loss is in the horizontal dimension, occurring mainly in the facial aspect of the ridge. There is also a loss of vertical ridge height, which is most pronounced in the buccal aspect [3], resulting in a narrower and shorter ridge [4]. Accordingly, the healing pattern after extraction may pose an esthetic problem in the case of implant-supported restoration fabrication [5].

Affiliation:

¹Oral Maxillofacial Surgery & Diagnostic Sciences Department, College of Dentistry, Riyadh Elm University, Riyadh, Saudi Arabia

²Oral Maxillofacial Radiology, University of Toronto, Toronto, Canada

³Restorative Dentistry at Princess Norah University, Clinical Dental Science Department, Riyadh, Saudi Arabia

⁴Riyadh Elm University Graduate, Riyadh, Saudi Arabia

⁵Advance General Dentistry (AGD), Ministry of National Guard - King Abdulaziz Medical City, Riyadh, Saudi Arabia

⁶Prosthodontic Department, Riyadh Elm University, Riyadh, Saudi Arabia

Corresponding author:

Ahmad Assari, Oral Maxillofacial Surgery & Diagnostic Sciences Department, College of Dentistry, Riyadh Elm University, Riyadh, Saudi Arabia

Citation: Ahmad Assari, Shereen Shokry, Dana Fayez Al-Senan, Tasnim Najed Alsbaih, Mada Awadh Alanazi, Mohammed Ahmed Alostaz. Relationship Between Maxillary Arch Shape And Maxillary Labial Bone Dimensions: A Pilot Study. *Dental Research and Oral Health*. 6 (2023): 12-20.

Received: February 22, 2022

Accepted: February 28, 2022

Published: March 05, 2023

The dimensions of the facial and lingual/palatal aspects of the alveolar process appear to be dependent on the eventual location and the size and inclination of the roots of erupted teeth [5]. It is generally believed that in subjects with different face heights, the masticatory muscle volume, cross-sectional area, and orientation of muscle fibers are different, which results in differences in the biting force on the facial and alveolar widths [6,7].

The dental arch form is defined as the curving shape formed by the configuration of the bony ridge. The basic characteristics of the arch form include the radius of curvature of the labial segment, intercanine width, and intermolar width. The dental arch size and shape undergo different changes throughout the growth of the supporting bones and the movement of teeth after eruption, and the perioral muscles and intraoral functional forces also aid in the configuration of the dental arch [8].

The literature lacks any studies that correlate the different arch shapes and the dimensions of the labial alveolar bone and an attempt to predict certain patterns of bone loss in relation to arch shape. Therefore, the aim of this study was to measure the thickness of the facial bone in the anterior portion of the maxilla at different locations apical to the alveolar bone crest and to determine whether it was related to the arch shape using cone beam computed tomography (CBCT).

Materials and Methods

Ethics statements

Ethical approval was obtained from the Ethics Committee at the Research Center of Riyadh Elm University with approval number FRP/2020/252/222/218, and the study was performed in accordance with the ethical standards as laid down in the 1964 Declaration of Helsinki and its later amendments.

Study design and population

Thirty cases were selected from the archived CBCT images at Riyadh Elm University. The inclusion criterion included

the presence of all maxillary front teeth, and the exclusion criteria included the presence of impacted, overlapping, unerupted, or extracted teeth of one of the six maxillary anterior teeth and teeth without clear bony boundaries that would prevent accurate measurements.

Measurements

The dimensions of the labial bones of the six anterior teeth were measured in each case. The distance between the cemento enamel junction (CEJ) and the alveolar crest and the labial bone wall thickness at different levels in relation to the alveolar crest were measured. The measurements were performed at 1, 3, and 5 mm from the crest of the alveolar ridge, as shown in figure 1.

The thickness of the alveolar bone at different locations is correlated with different maxillary arch shapes. Arch shapes were determined utilizing the axial images, and they were detected through the yellow curved axial arch plane indicator by tracing the incisal edges and buccal cusp tips of the maxillary teeth, where three arches form (U-shaped, V-shaped, and square-shaped) (Figure 2a-c). Measurements were performed using the Galileos CBCT 3D Digital Imaging System (Sirona, Germany). Images were obtained at 85 kV, 5-7 mA, and 14 seconds with a voxel size of 0.3 mm and field of view of 15 × 15 × 15.

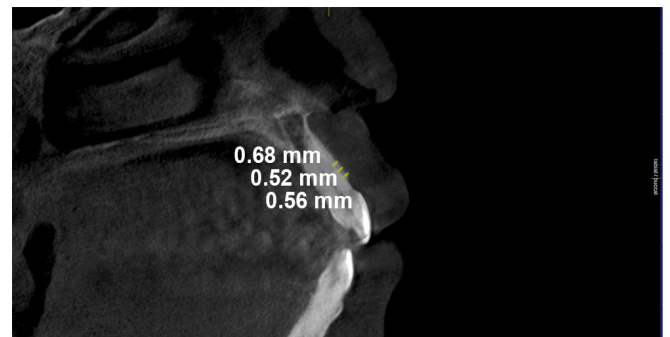


Figure 1: The locations of the measurements: 1 mm, 3 mm, and 5 mm from the crest to the cemento enamel junction. The thicknesses of the labial plate of the bone measured at specified locations

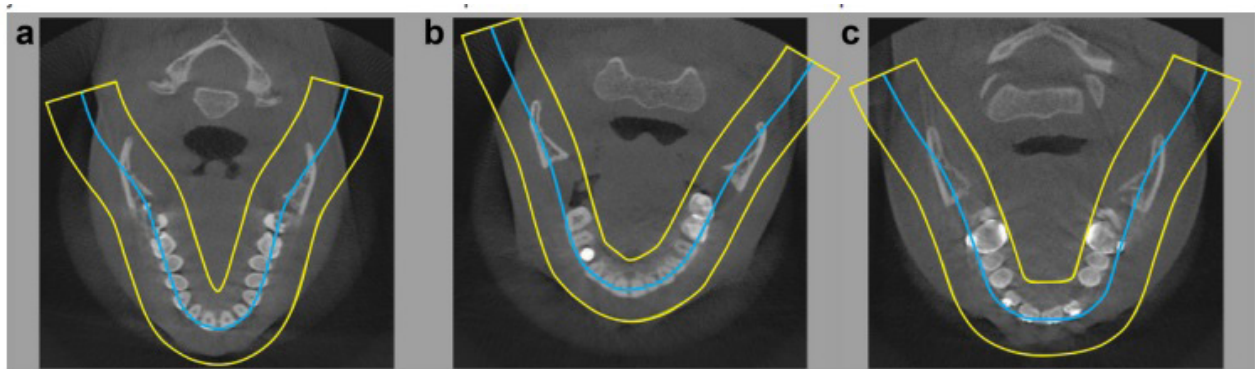


Figure 2: Different arch shapes: (a) V-shaped, (b) U-shaped (c), and square-shaped

Statistical analysis

The inter-observer agreement was excellent between authors when assessing both the labial bone thickness and the distance from the CEJ to the alveolar crest (intra-class correlation coefficient, 0.99 for all measured values). The kappa value was used for arch shape, and the inter-observer agreement was 0.63. All data were analyzed using statistical tests such as one-way analysis of variance (ANOVA), the chi-square test, multiple ANOVA (MANOVA), and the Tukey honestly significant difference (HSD) test. One-way ANOVA was used to compare the mean distance between the CEJ and the alveolar crest for the six anterior teeth. To determine whether there were any differences between the independent variables (arch shape and tooth) and dependent variables such as bone thickness at 1 mm, 3 mm, and 5 mm, MANOVA was used. All statistical analyses were performed using SPSS software version 20 (IBM Corp., Armonk, NY, USA), and $p < 0.05$ was considered statistically significant.

Results

The sample included nine men and 21 women (age range, 12-53 years). The mean distance between the CEJ and the alveolar crest for the six anterior teeth varied from 2.24 mm and 3.08 mm, with no significant difference between the teeth ($F(5, 154) = 1.45, p = 0.2$) (Figures 3 and 4). The mean bone wall thicknesses at 1, 3, and 5 mm from the alveolar crest for the six anterior teeth was not significantly different between the three measured distances, as shown in table 1.

In this study, the U-shaped arch was the most frequent

arch shape in women (62%), whereas the square-shaped arch was the most prevalent in men (78%) ($\chi^2 = 105.4, p = 0.001$). The Tukey HSD test showed a significant difference between the U-shaped arch on one side and both V-shaped and square-shaped arches on the other side, in terms of the labial bone wall thickness at 1 mm from the alveolar crest ($F(8, 276) = 3.24, p = 0.002$). The U-shaped arch showed the least bone wall thickness for all teeth (right central incisor: mean 0.56 mm, standard deviation [SD] 0.21 mm; left central incisor: mean 0.55 mm, SD 0.27 mm; right lateral incisor: mean 0.63 mm, SD 0.18 mm; left lateral incisor: mean 0.65 mm, SD 0.24 mm; right canine: mean 0.6 mm, SD 0.22 mm; and left canine: mean 0.4 mm, SD 0.21 mm), except for the left lateral incisor where the square-shaped arch presented the least labial bone wall thickness (mean 0.61 mm, SD 0.18 mm).

No significant differences were found in the mean distances between the CEJ and the alveolar crest for the six anterior teeth or the mean bone wall thicknesses at 1, 3, and 5 mm from the alveolar crest by sex (Table 2).

Ages were divided into five categories (12-20, 21-30, 31-40, 41-50, and 51-55 years), and a significant association was found between all measured variables including the level of the alveolar crest from the CEJ and the mean bone wall thicknesses at 1, 3, and 5 mm from the alveolar crest for the six anterior teeth. The Tukey HSD test revealed that the D-CEJ was significantly ($p = 0.006$) different between age groups 12-20, 21-30, and 31-40 years and age groups 41-50 and 51-55 years, as the younger groups had a smaller distance than the older groups.

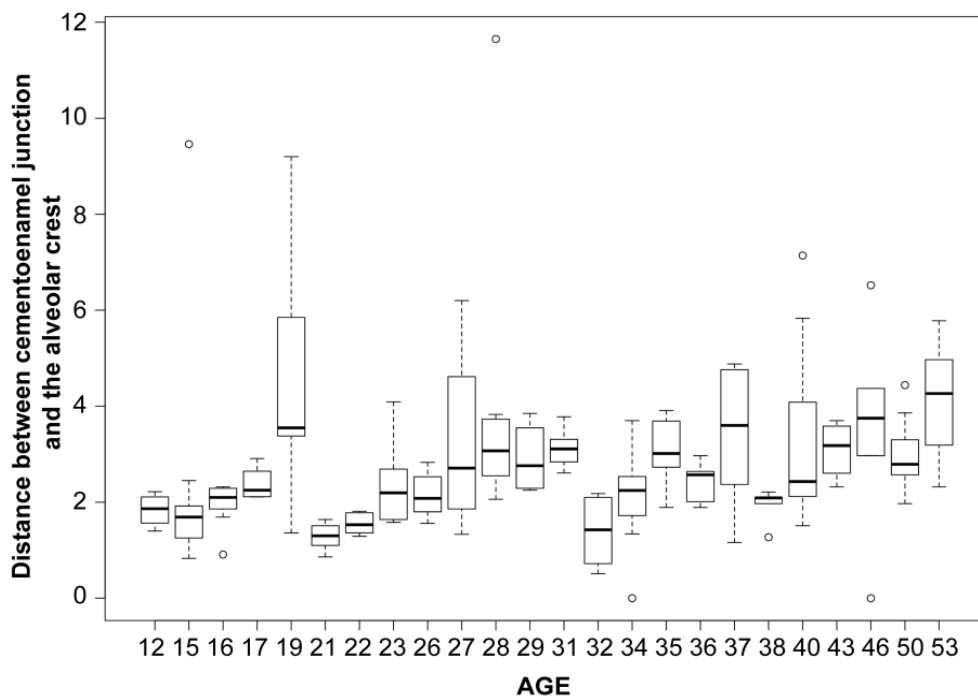


Figure 3: Distance between the cemento-enamel junction and the alveolar crest by age

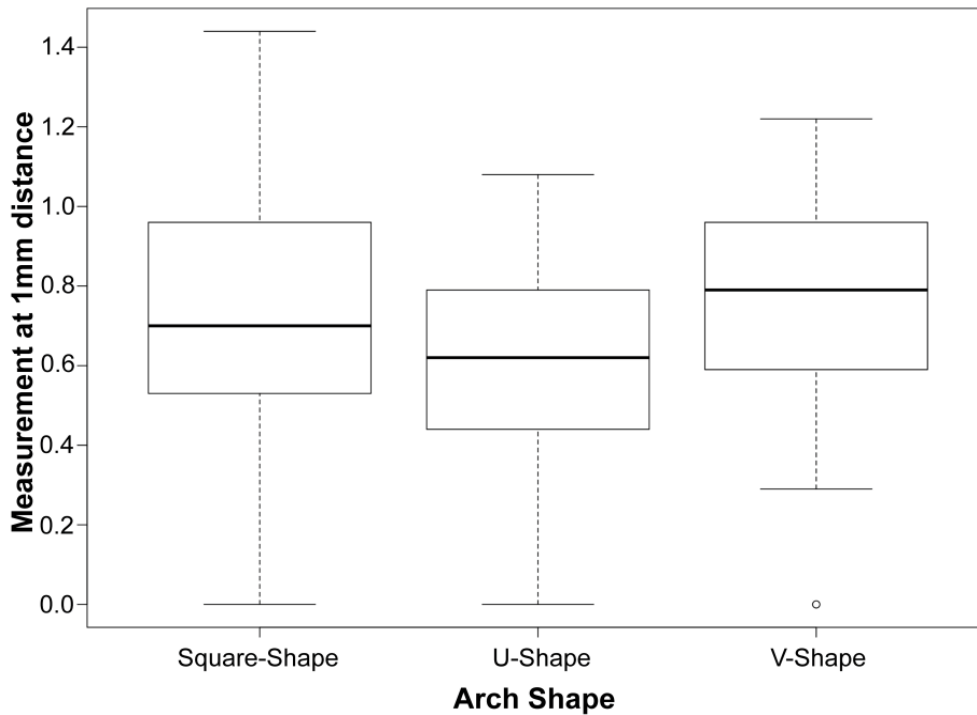


Figure 4: Distance between the cemento-enamel junction and the alveolar crest by arch shape

At 1 mm from the crest of the alveolar ridge, the age group of 12-20 years had the smallest bone wall thickness ($p = 0.001$) (Figure 5). At 3 mm from the crest of the alveolar ridge, the age group of 12-20 years had a lower bone wall thickness than the age group of 21-30 years ($p = 0.001$) (Figure 6). Finally, at 5 mm from the crest of the alveolar ridge, the bone wall thickness was larger in the age group of 21-30 years than in the age group of 12-20 years according to the Tukey HSD test ($p = 0.026$) (Table 3, Figure 7).

Discussion

Over the past 10 years, replacement of the anterior teeth using implants has received increased attention owing to their significant esthetic advantages [9]. However, the loss of facial bone due to resorption of the alveolar process immediately after tooth extraction is a major problem in treatment planning for implant placement [10-12]. In this pilot study, the results showed that the distance between the crest of the alveolar bone and the CEJ ranged between 2.24 and 3.08 mm. The distance was greatest for the lateral incisor, followed by the canines, and was the least for the central incisor. This result agrees with the findings of Januario et al. [12], in which the distance ranged from 1.6 to 3 mm, with the longest distance seen in the canines and shortest in the central incisors.

The thickness of the labial bone wall was <1 mm at all measured locations at 1, 3, and 5 mm from the crest of the alveolar ridge. The lowest thickness was found at 5 mm, with no significant difference between the measured thicknesses at 1 and 3 mm. These results are in agreement with the findings

of Huynh-Ba et al. [13], which showed that in more than 70% of the cases, the measured labial bone wall thickness is ≤ 0.5 mm.

Moreover, there was no significant difference between men and women regarding the distance between the crest of the alveolar ridge and the CEJ, or in bone thickness at 1 mm, 3 mm, and 5 mm from the crest of the alveolar ridge. Our findings are consistent with the findings of Braut et al. [14], who did not find any significant difference in the labial bone thickness between men and women.

The dimensions of alveolar bone are related to several factors. One of these factors, as stated in a previous study by Gracco et al., is that the thickness of alveolar bone in the maxillary anterior teeth is related to different facial types. It was found that individuals with a short facial type had thicker bones than individuals with a long facial type [15,16]. Furthermore, individuals with long faces had narrower arch dimensions, whereas those with short faces had wider arches [17].

Our study is the first to associate arch shape and labial alveolar bone wall thickness, where a significant association was found between U-shaped arches and bone wall thickness at 1 mm from the crest of the alveolar ridge. This finding may constitute a new indicator for the tendency of the labial alveolar bone to resorb after extraction and placement of endo-osseous implants. This could also be applied to orthodontic movement, where adequate incisal alveolar bone wall thickness is considered an anatomical limitation, as mentioned by Bajracharya [18].

Table 1: One-way analysis of variance of differences of the distance from the crest of the alveolar ridge to the cementoenamel junction for the six maxillary anterior teeth and differences in alveolar bone wall thicknesses at 1, 3, and 5 mm from the crest of the alveolar ridge

		N	Mean	SD	F	p-value
Dist-CEJ	Central Rt	28	2.2	0.8	1.47	0.2
	Central Lt	28	2.4	0.9		
	Lateral Rt	27	2.7	1.26		
	Lateral Lt	28	3.1	1.8		
	Canine Rt	23	2.9	1.78		
	Canine Lt	26	2.9	1.4		
	Total	160	2.68	1.4		
Alveolar bone wall thickness (1mm)	Central Rt	28	0.65	0.28	1.32	0.258
	Central Lt	28	0.67	0.25		
	Lateral Rt	27	0.79	0.28		
	Lateral Lt	28	0.64	0.2		
	Canine Rt	23	0.67	0.25		
	Canine Lt	26	0.72	0.29		
	Total	160	0.69	0.26		
Alveolar bone wall thickness (3mm)	Central Rt	28	0.6	0.25	0.67	0.644
	Central Lt	28	0.67	0.21		
	Lateral Rt	27	0.73	0.27		
	Lateral Lt	28	0.73	0.29		
	Canine Rt	23	0.7	0.25		
	Canine Lt	25	0.61	0.31		
	Total	159	0.68	0.26		
Alveolar bone wall thicknesses (5mm)	Central Rt	28	0.62	0.18	0.66	0.654
	Central Lt	28	0.61	0.25		
	Lateral Rt	27	0.61	0.39		
	Lateral Lt	28	0.57	0.29		
	Canine Rt	23	0.63	0.41		
	Canine Lt	25	0.49	0.28		
	Total	159	0.59	0.31		

Dist-CEJ, distance between the cementoenamel junction and the alveolar crest; Rt, right; Lt, left; SD, standard deviation

Table 2: One-way analysis of variance of the distance from the crest of the alveolar ridge to the cementoenamel junction for the six maxillary anterior and the difference in alveolar bone wall thicknesses at 1, 3, and 5 mm from the crest of the alveolar ridge by sex

		N	Mean	SD	F	p-value
Dist-CEJ	Male	48	2.8	1.33	0.44	0.51
	Female	112	2.6	1.41		
1 mm	Male	48	0.7	0.28	0.65	0.42
	Female	112	0.7	0.25		
3 mm	Male	48	0.7	0.25	0.42	0.52
	Female	111	0.7	0.27		
5 mm	Male	48	0.6	0.3	1.28	0.26
	Female	111	0.6	0.31		

Dist-CEJ, distance between the cementoenamel junction and the alveolar crest; SD, standard deviation

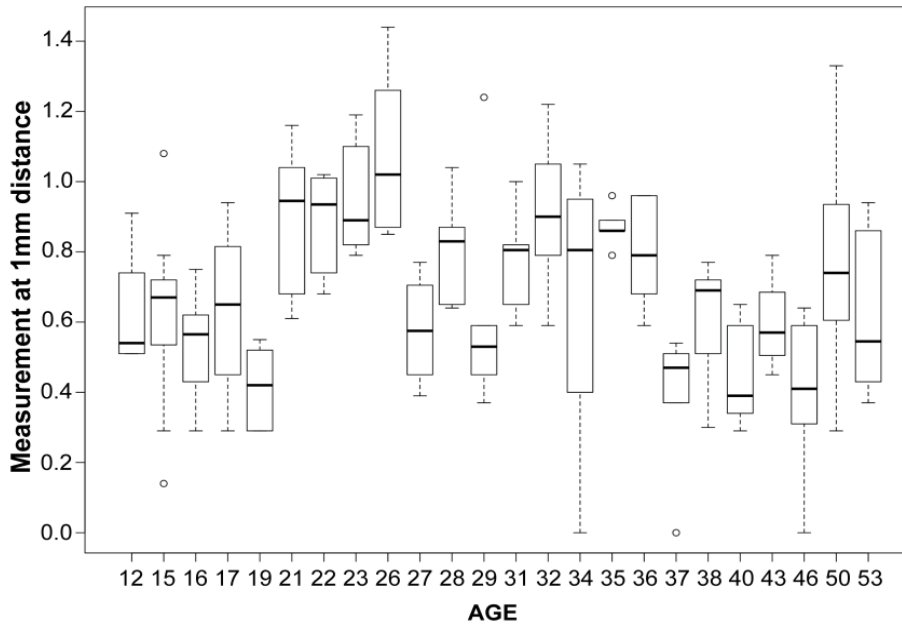


Figure 5: Differences in the measurement at 1 mm from the crest of the alveolar ridge by age

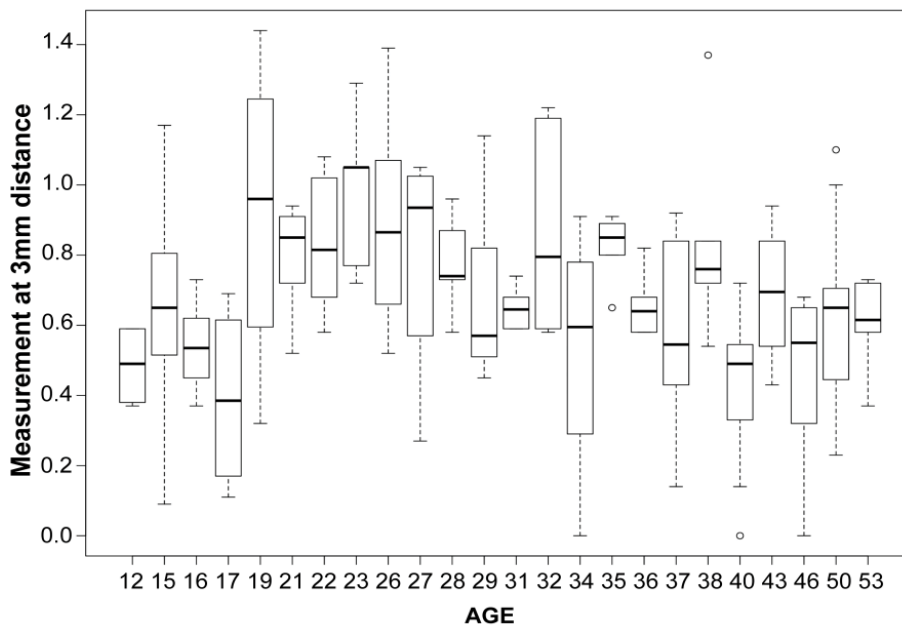


Figure 6: Differences in the measurement at 3 mm from the crest of the alveolar ridge by age

Previous studies have shown that crestal bone loss within the first year of implant insertion ranges from 0.9 to 1.6 mm [19-21]; thus, according to the current study, the arch shape could predict the site that is more susceptible to alveolar bone loss. Consequently, and in relation to our findings, patients with U-shaped arches will exhibit a higher tendency for maxillary labial bone loss following tooth extraction than those with other arch forms (V-shaped and square-shaped). This indicates that ridge preservation procedures should be performed immediately after extraction in patients with

U-shaped arches as a precautionary procedure, thus limiting horizontal and vertical ridge alterations in post-extraction sites.

Furthermore, it was found that the U-shaped arch was the most prevalent in women, who constituted the highest percentage of the studied population, whereas the square-shaped arch was the most prevalent arch shape in men. These findings disagree with those of a study that compared two different ethnic groups in Malaysia; Othman et al. [22] found

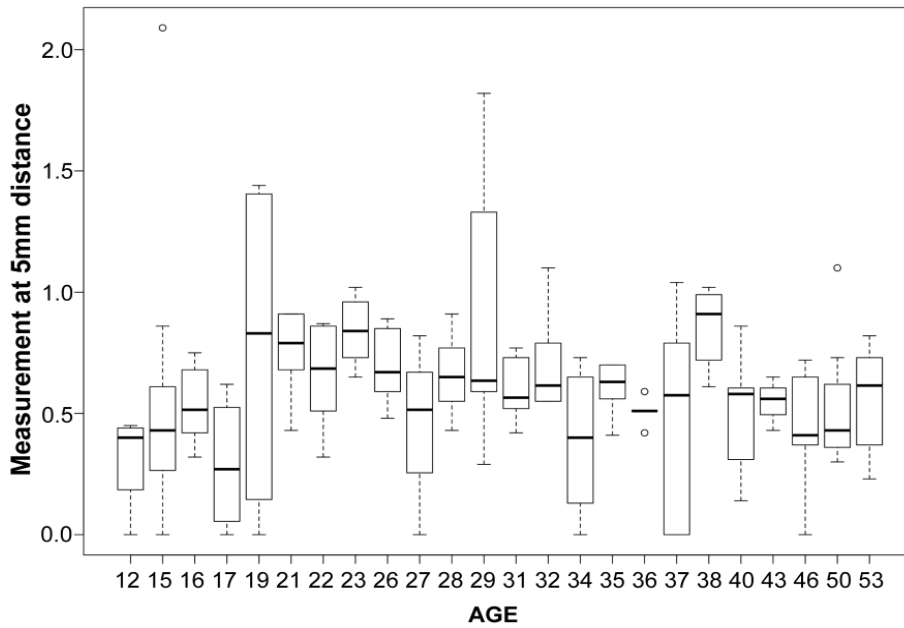


Figure 7: Differences in the measurement at 3 mm from the crest of the alveolar ridge by age-

Table 3: One-way analysis of variance of the distance from the crest of the alveolar ridge to the cemento-enamel junction for the six maxillary anterior teeth and the difference in alveolar bone wall thicknesses at 1, 3, and 5 mm from the crest of the alveolar ridge by different age groups

	Age (years)	N	Mean (mm)	SD (mm)	F	p-value
Dist-CEJ	12-20	34	2.5	1.9	3.74	0.006*
	21-30	44	2.3	1.02		
	31-40	56	2.7	1.2		
	41-50	20	3.3	1.02		
	51-60	6	4.1	1.29		
	Total	160	2.7	1.39		
1 mm	12-20	34	0.6	0.21	6.48	0.000*
	21-30	44	0.8	0.24		
	31-40	56	0.7	0.26		
	41-50	20	0.7	0.27		
	51-60	6	0.7	0.23		
	Total	160	0.7	0.26		
3 mm	12-20	33	0.6	0.28	5.01	0.001*
	21-30	44	0.8	0.23		
	31-40	56	0.6	0.27		
	41-50	20	0.6	0.23		
	51-60	6	0.6	0.13		
	Total	159	0.7	0.26		
5 mm	12-20	33	0.5	0.43	2.83	0.026*
	21-30	44	0.7	0.28		
	31-40	56	0.6	0.25		
	41-50	20	0.5	0.19		
	51-60	6	0.6	0.22		
	Total	159	0.6	0.31		

Dist-CEJ, distance between the cemento-enamel junction and the alveolar crest; SD, standard deviation

that although the most prevalent arch form was the U-shaped arch, there was no difference between sexes. Similarly, a study in India by Khunk and Madaan [23] found that 50% of the studied population had a U-shaped arch, with no significant difference between men and women, which also differs from the findings of our study.

Regarding different arch shapes, as reported in previous studies, the V-shaped arch was more prevalent in Caucasians, the square-shaped arch was more common in Koreans and Japanese, and the U-shaped arch was more common in Israelis [24-27]. Furthermore, different arch forms have an even distribution in the Egyptian population [25,28], whereas the square-shaped arch was more prevalent among the Vietnamese [25]. These variations in the morphology of the dental arches, with increased incidence of U-shaped arches, may act as an indicator of the thickness of the alveolar bone, and according to Belser [29], at least 2 mm of the labial bone wall should be available to ensure proper soft tissue support and to avoid resorption of the facial bone wall following restoration; otherwise, augmentation should be performed.

One limitation of this study is the limited number of cases studied. Further investigations with larger sample sizes should be conducted to determine if there is an exact correlation between different arch shapes and labial bone wall thickness.

Conclusions

In conclusion, our study is the first to associate arch shape and labial alveolar bone wall thickness. This association may constitute a new indicator for the tendency of the labial alveolar bone to resorb after extraction and placement of endo-osseous implants.

Compliance with ethical standards

Funding

None

Conflicts of interest

The authors declare that they have no conflict of interest.

Ethics approval

Ethical approval was obtained from the Ethics Committee at the Research Center of Riyadh Elm University, and the study was performed in accordance with the ethical standards as laid down in the 1964 Declaration of Helsinki and its later amendments.

Informed consent

This was a retrospective study on CBCT records, the IRB committee at the university approved the study following submission of a "source of data" form ensuring the confidentiality of the records.

Declarations

Consent to participate

This was a retrospective study on existing patients' records.

Author contributions

All authors contributed to the study conception and design. Material preparation, data collection were performed by Dana Fayez Al-Senan, Tasnim Najed Alsabih, Mada Awadh Alanazi, The manuscript was prepared by Shereen Shokry, Ahmad Assari and Mohammed Alostaz, it was read and approved by all authors.

Code availability

Not applicable.

Data availability

The datasets used and/or analysed during the current study are available from the corresponding author on reasonable request.

References

1. Kim HJ, Yu SK, Lee MH, et al. Cortical and cancellous bone thickness on the anterior region of alveolar bone in Korea: a study of dentate human cadavers. *J Adv Prosthodont* 4 (2012): 146-152.
2. Flanagan D. A comparison of facial and lingual cortical thicknesses in edentulous maxillary and mandibular sites measured on computerized tomograms. *J Oral Implantol* 34 (2008): 256-258.
3. Schroeder HE. The periodontium. In: Oksche A, Vollrath L (eds.) *Handbook of Microscopic Anatomy*, 5th edn. Springer, Berlin (1986): 233-246.
4. Pinho MN, Roriz VL, Novaes AB, et al. Titanium membranes in prevention of alveolar collapse after tooth extraction. *Implant Dent* 15 (2006): 53-61.
5. Van der WF, Dell'Acqua F, Slot DE. Alveolar bone dimensional changes of post-extraction sockets in humans: a systematic review. *J Clin Periodontol* 36 (2009): 1048-1058.
6. Anwar N, Fida M. Clinical applicability of variations in arch dimensions and arch forms among various vertical facial patterns. *J Coll Physicians Surg Pak* 21 (2011): 685-690.
7. Chan HG, Woods M, Stella D. Mandibular muscle morphology in children with different vertical facial patterns: a 3-dimensional computed tomography study. *Am J Orthod Dentofacial Orthop* 133 (2008): 1-13.
8. Owais AI, Abu Alhaja ES, Oweis RR, et al. Maxillary

- and mandibular arch forms in the primary dentition stage. *Oral Health Dent Manag* 13 (2014): 330-335.
9. Bartee BK. Extraction site reconstruction for alveolar ridge preservation. Part 1: rationale and materials selection. *J Oral Implantol* 27 (2001): 187-193.
 10. Elias AC, Sheiham A. The relationship between satisfaction with mouth and number and position of teeth. *J Oral Rehab* 25 (1998): 109-128.
 11. Palmer RM, Palmer PJ, Newton T. Dealing with esthetic demands in the anterior maxilla. *Periodontol* 33 (2003): 105-118.
 12. Januario AL, Duarte WR, Barriviera M, et al. Dimension of the facial bone wall in anterior maxilla: a cone-beam computed tomography study. *Clin Oral Impl Res* 22 (2011): 1168-1171.
 13. Huynh-Ba G, Pjetursson BE, Sanz M, et al. Analysis of the socket bone wall dimensions in the upper maxilla in relation to immediate implant placement. *Clin Oral Implants Res* 21 (2010): 37-42.
 14. Braut V, Bornstein MM, Belser U, et al. Thickness of the anterior maxillary facial bone wall—a retrospective radiographic study using cone beam computed tomography. *Int J Periodontics Restorative Dent* 31 (2011): 125-131.
 15. Gracco A, Lombardo L, Mancuso G, et al. Upper incisor position and bony support in untreated patients as seen on CBCT. *Angle Orthod* 79 (2009): 692-702.
 16. Zhou Z, Chen W, Shen M, et al. Cone beam computed tomographic analyses of alveolar bone anatomy at the maxillary anterior region in Chinese adults. *J Biomed Res* 28 (2014): 498-505.
 17. Khera AK, Singh GK, Sharma VP, et al. Relationship between dental arch dimensions and vertical morphology in class I subjects. *J Ind Orthod Soc* 46 (2012): 316-324.
 18. Bajracharya M. Analysis of maxillary bone thickness at incisor area in class II division 1 malocclusion. *Orthodont J Nepal* 1 (2011): 42-46.
 19. Alshehri MA. The maintenance of crestal bone around dental implants. *Implants* 12 (2011): 30-36.
 20. Cochran DL, Nummikoski PV, Schoolfield JD, et al. A prospective multicenter 5-year radiographic evaluation of crestal bone levels over time in 596 dental implants placed in 192 patients. *J Periodontol* 80 (2009): 725-733.
 21. Hermann JS, Buser D, Schenk RK, Cochran DL. Crestal bone changes around titanium implants. A histometric evaluation of unloaded non-submerged and submerged implants in the canine mandible. *J Periodontol* 71 (2000): 1412-1424.
 22. Othman SI, Xinwei ES, Jamaludin M, et al. Comparison of arch form between ethnic Malays and Malaysian Aborigines in Peninsular Malaysia. *Korean J Orthod* 42 (2012): 47-54.
 23. Khatri JM, Madaan JB. Evaluation of arch form among patients seeking orthodontic treatment. *J Ind Orthod Soc* 46 (2012): 325-328.
 24. Gafni Y, Tzur-Gadassi L, Nojima K, et al. Comparison of arch forms between Israeli and North American white populations. *Am J Orthod Dentofacial Orthop* 139 (2011): 339-344.
 25. Kil-Jun Lee KJ, Trang VT, Bayome M, et al. Comparison of mandibular arch forms of Korean and Vietnamese patients by using facial axis points on three-dimensional models. *Korean J Orthod* 43 (2013): 288-293.
 26. Kook YA, Nojima K, Moon HB, et al. Comparison of arch forms between Korean and North American white populations. *Am J Orthod Dentofacial Orthop* 126 (2004): 680-686.
 27. Nojima K, McLaughlin RP, Isshiki Y, et al. A comparative study of Caucasian and Japanese mandibular clinical arch forms. *Angle Orthod* 71 (2001): 195-200.
 28. Bayome M, Sameshima GT, Kim Y, et al. Comparison of arch forms between Egyptian and North American white populations. *Am J Orthod Dentofacial Orthop* 139 (2011): e245-e252.
 29. Belser UC. Replacement of an upper left persisting deciduous canine with a regular neck implant, restored with a ceramometal crown, horizontally screw-retained. In: Buser D, Belser U, Wismeijer D (eds). *ITI Treatment Guide, vol 1: Implant Therapy in the Esthetic Zone—Single-Tooth Replacements*. Quintessence, Berlin (2006): 159-177.