

Case Report

## Atypical Finishing with Lower Incisor Missing and Lower Primary Canine Retained using Improved Super-Elastic Ti-Ni Alloy Wire and Aligners

Lo Yu-Cheng<sup>1</sup>, Chen Yuan-Hou<sup>1,2</sup>, Chiang Hsien-Hsiung<sup>1,2</sup>, Yu Jian-Hong<sup>1\*</sup>

<sup>1</sup>Department of Orthodontics, China Medical University Hospital, Taichung City, Taiwan

<sup>2</sup>National Taiwan University, Taipei, Taiwan

\***Corresponding Author:** YU Jian-Hong, Department of Orthodontics, China Medical University Hospital, No. 2, Yude Road, North District, Taichung City 404, Taiwan, R.O.C., Tel: +886 (04) 2205 2121; Fax: +886 (04) 2208 3403; E-mail: [kenkoyu@hotmail.com](mailto:kenkoyu@hotmail.com)

---

**Received:** 04 October 2019; **Accepted:** 14 October 2019; **Published:** 04 November 2019

**Citation:** Lo Yu-Cheng, Chen Yuan-Hou, Chiang Hsien-Hsiung, Yu Jian-Hong. Atypical Finishing with Lower Incisor Missing and Lower Primary Canine Retained Using Improved Super-Elastic Ti-Ni Alloy Wire and Aligners. Dental Research and Oral Health 2 (2019): 053-061.

### Abstract

**Introduction:** This is an atypical finish case with extraction of bilateral deciduous canines and three incisor finishing due to lower lateral incisor congenital missing replaced by 1<sup>st</sup> premolars. We used improved super-elastic Ti-Ni alloy wire (ISW) for anterior anchorage preparation during the molar mesial drive. Aligners for finishing and detailing were adopted because patient was ordered to an international expatriate job. We are going to discuss the mechanism we used, atypical finishing consideration and timing for aligners using.

**Findings:** This case report describes an adult female patient with lower incisor missing, lower bilateral primary canines retained, and dental crossbite. All were treated successfully with improved super-elasticity Ti-Ni alloy wire and aligners.

**Conclusions:** After the treatment, a desirable outcome was achieved and the patient was pleased with the treatment result. To sum up, wire orthodontics (WO) and aligner orthodontics (AO) will be a flexible and humanity treatment strategy for patients in the future.

**Keywords:** Angle Class III; Atypical finishing; Primary canine retained; ISW; Aligners

Many parameters were not within ideal ranges. In particular, the L1 to Mandibular: 86.9°. Clinical examination showed no signs of bad habits (Figures 4 and 5).

### 1. Introduction

An adult female (26 years old) came to our clinic with a chief complaint of poor dental alignment. Clinical examination revealed Angle Class III. We used ISW (Improved super-elastic Ti-Ni alloy wire) [1, 2] to correct canine crossbite over the upper left area and relieve the crowding. Elastic chains were also used to perform molar mesial drive [3] and to achieve intercuspal interdigitation. For anchorage preparation, we used only two stoppers to maintain the arch length. Aligners for finishing and detailing were adopted. In the end, correction of arch coordination, space management and bite control were successfully achieved.

### 2. Case Report

This case report describes an adult female patient with lower incisor missing, lower bilateral primary canines retained, and dental crossbite. All were treated successfully with improved super-elasticity Ti-Ni alloy wire and aligners.

#### 2.1 Diagnosis and etiology

A 26 years old female with a straight profile came to our clinic for orthodontic consultation. Extra-oral and frontal profile revealed adequate incisor exposure; but upper midline deviation towards the left with respect to the facial midline were present (Figure 1). Clinical examination revealed Angle Class III tendency with upper left canine crossbite, bilateral lower primary canines retained, #31 congenital missing, and crowding in both arches (Figure 2). Panoramic radiography revealed #31, #33, #43 missing, no unerupted tooth, no infection and no temporomandibular joint abnormalities (Figure 3). Cephalometric film showed skeletal Class III from mandibular prostrusion, and a straight facial type (ANB: -0.6°) and a mandibular plane angle of 27.5°.

#### Facial photos

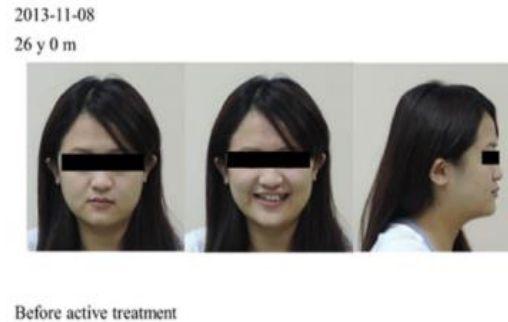


Figure 1: Pre-treatment extraoral photos.

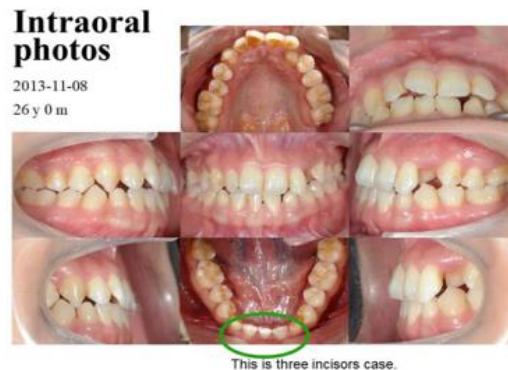

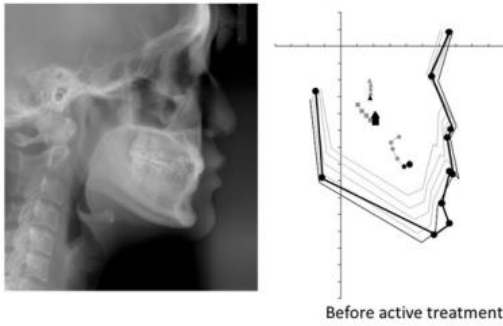
Figure 2: Pre-treatment intraoral photos.

#### X-ray findings (1)

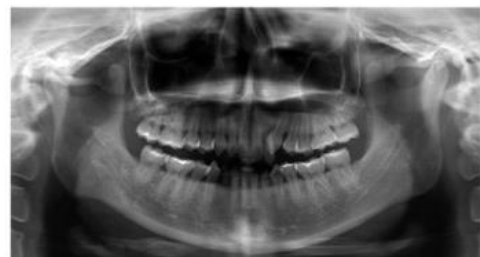

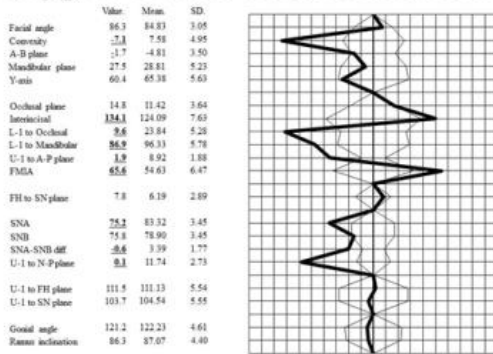
Figure 3: Pre-treatment panoramic radiograph.

**X-ray findings (2)**



**Figure 4:** Pre-treatment cephalometric radiographs with profilogram.

**Polygon- Before active treatment**



**Figure 5:** Pre-treatment cephalometric polygon.

**2.2 Treatment objectives**

The patient came to our clinic with a chief complaint of poor dental alignment and small morphology of lower bilateral primary canines with some tooth mobility. The first priority of objectives were to solve the chief complaint, so as to achieve molar and canine Class I relationship and to achieve upper midline coincident with facial midline. Other objectives were to correct the crowding and #23 crossbite, improved overjet and overbite, and to obtain a better arch coordination and an individual normal occlusion.

**2.3 Treatment alternatives**

1. Orthodontic treatment combined with orthognathic surgery

2. Orthodontic treatment combine with prosthodontic treatment.
3. Orthodontic treatment combined with mini- screws.
4. Orthodontic treatment without mini-screws.

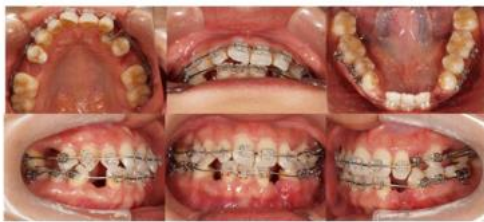There were mild maxillary discrepancies, the ideal treatment for the patient was orthodontic treatment combined with orthognathic surgery. Le Fort I and Bilateral sagittal split surgery could do maxillary advancement and mandible setback to improved her facial profile [4]. If the skeletal problem were solved, the orthodontic treatment would be easier. However, the patient refused any proposal of surgery including mini-screw insertion. So the treatment combined with surgery was rejected. The second option was prosthodontic treatment combined with orthodontic treatment, but lower primary canines had poor crown root ratio (crown:root = 2:1) [5]. This ratio is a measurement of the length of tooth occlusal to the alveolar crest of bone compared with the length of root embedded in the bone. Ideally, a clinical crown to root ration is 2:3. Minimally, 1:1 for a tooth is considered for use as an abutment. Thus, prosthodontic treatment for the #73 and #83 won't be a good idea [6]. The third option would be extraction of #15, #25, #73 and #83, Using mini-scews help with molar mesial drive, but this patient was a little bit dental-phobia about any minor surgery. The fourth treatment was upper 2<sup>nd</sup> premolar and lower bilateral primary canines extracted for crowding relief and to achieve an ideal Bolton's ratio, but molar mesial drive and atypical finish will be an interesting issue. In the end, this patient agreed to undergo orthodontic treatment for dental camouflage only.

**2.4 Treatment progress**

After thorough explanation and discussion of the treatment options, the patient agreed to receive

orthodontic treatment without surgical approach and without mini-screw insertion. This study discussed improved super-elastic Ti-Ni alloy wire (ISW; developed by Tokyo Medical and Dental University, Japan) for the treatment of Angle Class III with molar mesial drive case. The properties and characteristics of ISW are super-elasticity, shape memory, and shock and vibration absorption property. This article describes the experiences of treating a case using ISW combined with intermaxillary elastics (IME's) and stoppers to perform molar mesial drive. This helped the patient gain an esthetically pleasing smile with which she was satisfied. On 2014-01-06, we applied direct bonding system (DBS) with 0.018 × 0.025-inch brackets over the upper and lower arches. We used a 0.016 × 0.022-inch ISW to level the teeth for 3 months, preliminary leveling and alignment were gradually achieved (Figure 6).

#### Start of active treatment



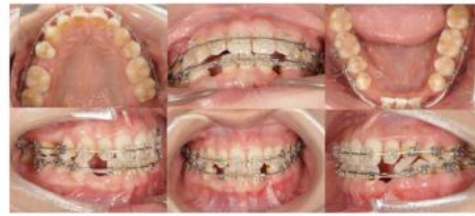2014-01-06 Upper and lower arch DBS, leveling with 0.016x0.022 ISW. ISW could provide an efficient omni-directional control.

Period of active treatment: 0 m

**Figure 6:** Start of active treatment: Upper and lower arch DBS, leveling with 0.016x0.022 ISW.

On 2014-05-17, after 4 months of active treatment, crossbite at #23 was corrected by ISW fully engaged and bracket-upside-down(b-u-d) for correction of root torque (Figure 7).

#### Canine crossbite corrected



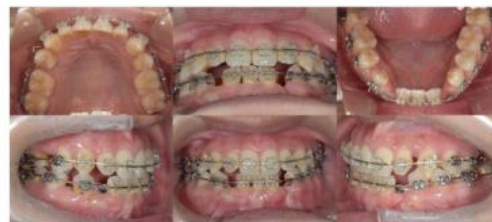2014-05-17 Crossbite at 23 was corrected by ISW fully engaged.

Period of active treatment: 4 m

**Figure 7:** Canine crossbite corrected: Crossbite at 23 was corrected by ISW fully engaged.

On 2014-12-20, after 11 months of active treatment, upper incisors were flared out by 0.016x 0.022 ISW. Both #34 and #44 mesial drives were done by elastic chains, while lower arch length was maintained by two stoppers placed mesial to #36 and #46. While we protracted #34 and #44, the opposite forces were against anterior 3 incisors and thus stoppers were placed mesial to the molar areas. This method is referred to as the “10-2”(10 teeth vs. 2 teeth) anchorage system, and it allows a quickly controlled response without serious adverse reaction [7, 8] (Figure 8).

#### Lower 1st Premolars mesial drive



2014-12-20 Upper incisors were flared out by 0.016x 0.022 ISW. Both 34, 44 mesial drives were done by elastic chain, while lower arch length was maintained by two stoppers placed mesial to 36 and 46.

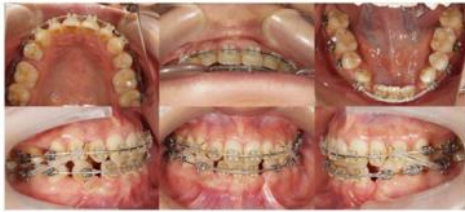Period of active treatment: 11 m

**Figure 8:** Lower 1st Premolars mesial drive.

On 2015-09-05, after 20 months of active treatment, Class II IME was used to reinforce the anchorage. (R:#13-#46 L:#23-#36) (Figure 9).



### Anchorage preparation and Premolar mesial drives (continued)



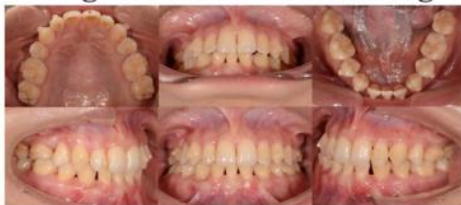2015-09-05 Class II IME was used to reinforce anchorage. (R:13-46 L:23-36)

Period of active treatment: 20 m

**Figure 9:** Anchorage preparation and Premolar mesial drives (continued).

On 2018-02-03, after 49 months of active treatment, patient got an international expatriate job by her company so that brackets should be debonded. Aligner attachments bonded for detailing were adopted for further detailing of the treatment (Figure 10). Aligners for torque control and mild space closure between #34 and #32 were used on 2018-04-18 (Figure 11). On 2018-07-07 circumferential retainer was delivered for the upper arch. And Hawley retainer was delivered at the lower arch for retention (Figure 12).

### Brackets debonding and aligner attachments bonding

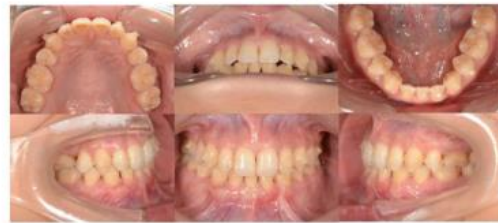

2018-02-03: Bracket debonding. Aligner attachments bonding for detailing.

Period of active treatment: 49 m

**Figure 10:** Brackets debonding and aligner attachments bonding.

### Aligner for Finishing and Detailing

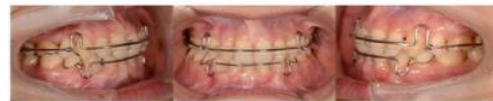

2018-04-18 Aligner for torque control and mild space closure between 34 and 32.

Period of active treatment: 51 m

**Figure 11:** Aligner for Finishing and Detailing.

### Retention



2018-07-07 Circumferential retainer was delivered at the upper arch. Hawley retainer was delivered at the lower arch.

Period of active treatment: 54 m

**Figure 12:** Circumferential retainer for the upper arch. Hawley retainer for the lower arch.

### 3. Treatment Results

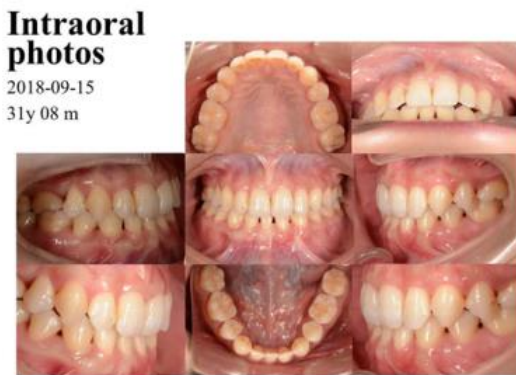After 54 months of active treatment, extra-oral appearance and intra-oral examination were improved. The straight profile, lower facial height, correlated facial midlines were achieved (Figure 13). Intra-oral, Class I canine and molar relationships were also achieved with good interdigitation, normal overbite and overjet, and curve of Spee. The smile arc became more harmonious after treatment (Figures 13 and 14). The post-treatment cephalometric analysis (Figures 15 and 16) and the superimposed cephalometric tracings (Figures 17 and 18) demonstrate a significant improvement, pre-treatment ANB:  $-0.6^\circ$  improved to ANB:  $0.3^\circ$  and Mandibular plane was  $27.5^\circ$  to  $27.8^\circ$ . Dental analysis of pre-treatment and post-treatment was U1 to FH plane from  $111.5^\circ$  to  $105.6^\circ$  and L1 to

mandibular plane was from 86.9° to 82.5°. Dental parameters were acceptable.

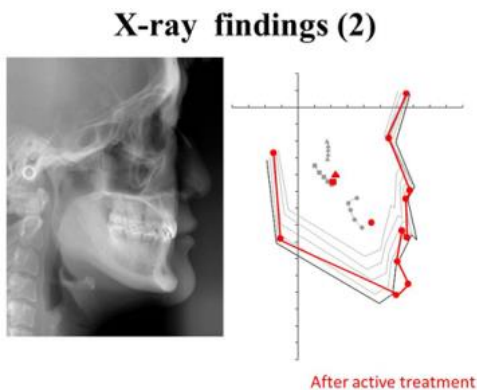


After active treatment

**Figure 13:** Post-treatment extraoral photos.

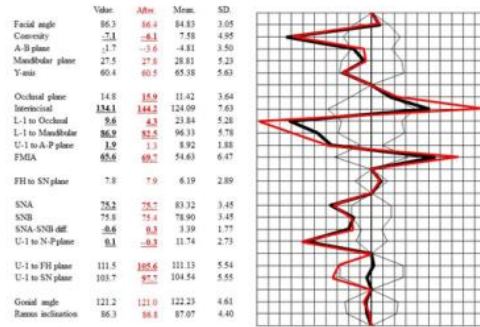


**Figure 14:** Post-treatment intraoral photos.



**Figure 15:** Post-treatment cephalometric radiographs with profilogram.

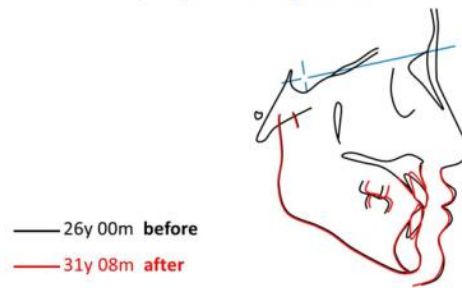
**Polygon-After active treatment**



**Figure 16:** Post-treatment cephalometric polygon.

**Superimposition (1)**

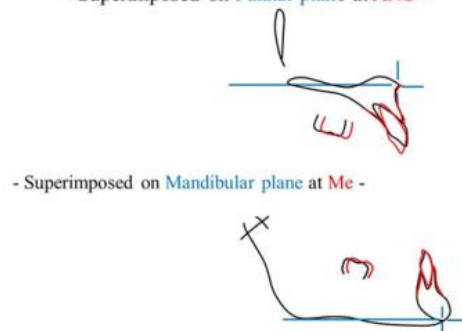
- Superimposed on SN plane at S -



**Figure 17:** Superimposition of lateral cephalometric tracings. Black line, before treatment; red line, after treatment.

**Superimposition (2)**

- Superimposed on Palatal plane at ANS -



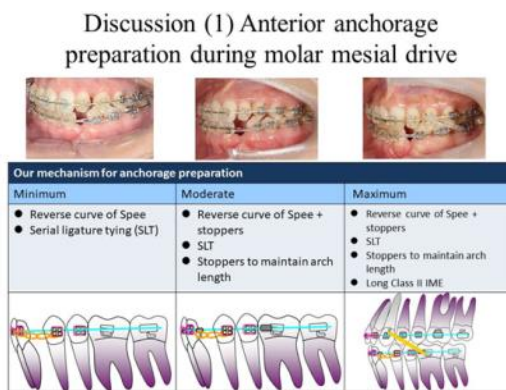
**Figure 18:** Maxillary superimposition and mandibular superimposition.

At the end of treatment, we gave the patient a circumferential retainer at the upper arch, a Hawley retainer at the lower arch, and an auxiliary clear plastic

retainer for retention [9]. The treatment outcome maintained stable after several appointments of recalls.

#### 4. Discussion

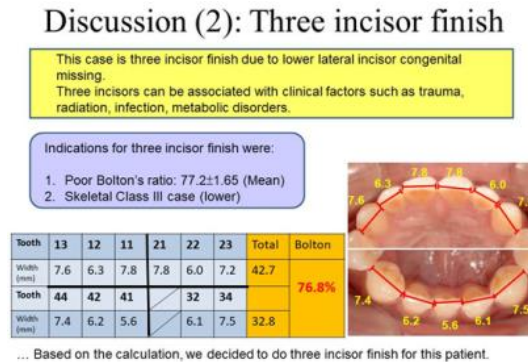
We used ISW for anterior anchorage preparation during molar mesial drive. Our mechanisms for anchorage preparation have three types, minimum anchorage could use reverse curve of Spee with series ligature tying over the anterior teeth. While protracting the teeth forward, the reciprocal forces were against the anterior incisors and stoppers were placed mesial to bilateral molars area. The maximum anchorage could be long Class II intermaxillary elastics to reinforce the anchorage (Figure 19).



**Figure 19:** Discussion (1) Anterior anchorage preparation during molar mesial drive.

This case is three incisor finish due to lower lateral incisor congenital missing. Incisor congenital missing can be associated with clinical factors such as trauma, radiation, infection, metabolic disorders [10]. Indications for three incisor finish were due to poor Bolton's ratio and skeletal Class III case due to upper and lower arch discrepancy. The ideal Bolton's ratio is 77.2% [11, 12]. Width of #73 and #83 are 5.4 mm and 5.2 mm respectively. If primary canines retained for restoration, we should create 4.5 mm for better Bolton's ratio. If using 1<sup>st</sup> premolar for canine substitution, the Bolton's ratio in this case is 76.8%. Based on the

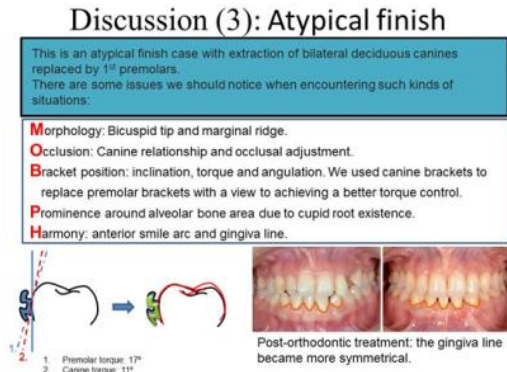
calculation, we decided to do three incisor finish for this patient (Figure 20).



**Figure 20:** Discussion (2): Three incisor finish.

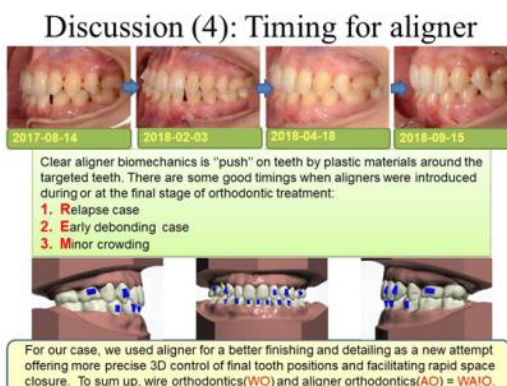This is an atypical finish case with extraction of bilateral deciduous canines replaced by 1<sup>st</sup> premolars. There are some issues we should notice when encountering such kinds of situations: The difference of 1<sup>st</sup> premolar substitution for canine [13] are (1) Premolar morphology is bicuspid and is different from canine single cusp. Fortunately, functional cusp of lower premolar is buccal cusp and lingual cusp is non-functional, besides lingual cusp tip is lower than the buccal cusp. So the occlusal interference won't be a serious problem; (2) Compared with bilateral lower primary retained canines, premolar substitution had an adequate mesiodistal widths for canine Class I relationship achievement; (3) Bracket position: inclination, torque and angulation... We used canine brackets to replace premolar brackets with a view to achieving a better torque control (premolar torque: 17° replace with canine torque: 11°) and reduce canine overjet; (4) Mandibular 1<sup>st</sup> premolar root usually has one root which resembles as canine root with oval shape. The prominence around alveolar bone area was similar. (5) Harmony: detection of anterior smile arc and gingiva line (Figure 21).





**Figure 21:** Discussion (3): Atypical finish.

After the final stage of detailing, this patient was ordered to an international expatriate job by her company, so we consider the timing and necessity for aligner intervention. There are some good advantages of aligner, for example brushing and flossing is easier, removable, invisible, and the most important factors which we decided to use in our treatment is to reduce orthodontic emergency in other countries. Traditional orthodontic emergency including ligature wire coming off, loose brackets or bends, protruding wire and so on. We summarized three timings to use aligners: (1) relapsed case; (2) early debonding cases; and (3) minor crowding. Aligner are effective and with good efficacy for such cases [14] (Figure 22).



**Figure 22:** Discussion (4): Timing for aligner.

## 5. Conclusions

In this case, we used aligners for a better finishing and detailing as a new attempt offering more precise 3D control of final tooth positions and facilitating rapid space closure. ISW and aligner can provide a multi-directional control for this kind of malocclusion and patient's conditions. After the treatment, a desirable outcome was achieved and the patient was pleased with the treatment result. To sum up, wire orthodontics(WO) and aligner orthodontics(AO) will be a flexible and humanity treatment strategy for patient in the future.

## Acknowledgements

The authors declare that they have not received funding.

## Availability of data and materials

The authors declare that the materials are available.

## Authors' contributions

YJH is responsible for the treatment planning decision. LYC responsible for clinical patient treatment. LYC, CYH and CHH did the article test production. All authors read and approved the final manuscript.

## Ethics approval and consent to participate

The study was performed in accordance with the Declaration of Ms.Tsai. It is a case report, and the treatment plan was approved by the Chairman of department of Orthodontics, China Medical University.

## Consent for publication

Written informed consent was obtained from the patient for publication of this short report and any accompanying images.

## Conflicts of interest

The authors declare that they have no Conflicts of interest.



## References

1. Miura F, Mogi M, Ohura Y, Hamanaka H. The Superelastic Property of the Japanese NiTi Alloy Wire for use in Orthodontics. *American Journal of Orthodontics and Dentofacial Orthopedics* 90 (1986): 1-10.
2. Lai WJ, Midorikawa Y, Kanno Z, Takemura H, Suga K, Soga K, et al. A New Orthodontic Force System for Moment Control Utilizing the Flexibility of Common Wires: Evaluation of the Effect of Contractile Force and Hook Length. *Journal of the Formosan Medical Association* 117 (2018): 71-79.
3. Baik UB, Choi HB, Kim YJ, Lee DY, Sugawara J, Nanda R. Change in Alveolar Bone Level of Mandibular Second and Third Molars after Second Molar Protraction into Missing First Molar or Second Premolar Space. *European Journal of Orthodontics* 41 (2019): 513-518.
4. Proffit WR, White RP. *Combined Surgical-Orthodontic Treatment- Who Does What When?* Surgical-Orthodontic Treatment. 1st ed. Chicago: Mosby (1991).
5. Penny RE, Kraal JH. Crown-to-Root Ratio: Its Significance in Restorative Dentistry. *The Journal of Prosthetic Dentistry* 42 (1979): 34.
6. Nyman S, Lindhe J, Lundgren D. The Role of Occlusion for the Stability of Fix Bridges In Patient With Reduced Periodontal Tissue Support. *Journal of Clinical Periodontology* 2 (1975): 53.
7. Klontz HA. Tweed-Merrifield Sequential Directional Force Treatment. *Seminars in Orthodontics* 2 (1986): 254.
8. Merrifield LL. Edgewise Sequential Directional Force Technology. *Journal of the Charles H. Tweed International Foundation* 14 (1986): 22.
9. Zachrisson BU. Important Aspects of Long-Term Stability. *American Journal of Orthodontics and Dentofacial Orthopedics* 112 (1997): 596-606.
10. Aktan AM, Kara I, Sener I, Bereket C, Celik S, Kirtay M, et al. An Evaluation of Factors Associated with Persistent Primary Teeth. *European Journal of Orthodontics* 34 (2012): 208-212.
11. Bolton WA. Disharmony in Tooth Size and its Relation to the Analysis and Treatment of Malocclusion. *The Angle Orthodontist* 28 (1958): 112-130.
12. Bolton WA. The Clinical Application of a Tooth-Size Analysis. *American Journal of Orthodontics* 48 (1962): 504-529.
13. Mirabella D, Giunta G, Lombardo L. Substitution of Impacted Canines by Maxillary First Premolars: A Valid Alternative to Traditional Orthodontic Treatment. *American Journal of Orthodontics and Dentofacial Orthopedics* 143 (2013): 125-133.
14. Zheng M, Liu R, Ni Z, Yu Z. Efficiency, Effectiveness and Treatment Stability of Clear Aligners: A Systematic Review and Meta-Analysis. *Orthodontics & Craniofacial Research* 20 (2017): 127-133.



This article is an open access article distributed under the terms and conditions of the

[Creative Commons Attribution \(CC-BY\) license 4.0](https://creativecommons.org/licenses/by/4.0/)