

Case Report

Oral Manifestation of a Systemic Bleeding Diathesis with Fatal Outcome: A Holistic Approach to Assessment

Raphael Figueroa, Mahnaz Fatahzadeh*

Department of Diagnostic Sciences, Rutgers School of Dental Medicine, Newark, NJ-USA

***Corresponding Author:** Mahnaz Fatahzadeh, Department of Diagnostic Sciences, Rutgers School of Dental Medicine, 110 Bergen Street Newark, NJ-USA, Tel: 973-972-1956; E-mail: fatahza@sdm.rutgers.edu

Received: 19 September 2019; **Accepted:** 01 October 2019; **Published:** 30 October 2019

Citation: Raphael Figueroa, Mahnaz Fatahzadeh. Oral Manifestation of a Systemic Bleeding Diathesis with Fatal Outcome: A Holistic Approach to Assessment. Dental Research and Oral Health 2 (2019): 047-052.

Abstract

Oral cavity is the mirror of body health and disease and the relationship between oral and systemic health is multi-faceted and reciprocal. In fact, many systemic conditions could manifest in the oral region, sometimes prior to their diagnosis. Dentists are physicians of the oral cavity and a holistic approach to patient assessment can guide dental providers in differentiating between oral abnormalities of local and systemic origin and deciding on appropriate management.

Keywords: History; Physical exam; Holistic; Oral-systemic connection; Bleeding

1. Introduction

Sir William Osler, the father of modern medicine, revolutionized medical education by incorporating bedside teaching and his emphasis on diagnostic skills

[1]. This clinical approach is reflected in his well-known quotes such as “Listen to your patients, they are telling you the diagnosis”, “one finger in the throat and one finger in the rectum makes a good diagnostician” and The good physician treats the disease; the great physician treats the patient who has the disease. [2-4]. These simple yet profound statements sum up the value of holistic approach to patient assessment as a foundation for diagnosis and prioritizing care-an art which should not be overlooked by clinicians burdened by the daily stressors of private practice. The diagnostic process relies on the ability of a clinician to synthesize patient’s past medical history, presenting symptoms, risk factors and physical signs to develop a prioritized list of differential diagnoses. The latter would be narrowed down by gathering additional information or diagnostic testing until a definitive diagnosis is

established [5]. A thorough history is not only the oldest, but also the most reliable element in the diagnostic work up [5-7]. An astute clinician is not only an active listener capable of eliciting pertinent information, but also observant of non-verbal clues critical to diagnosis during the medical interview [6, 7]. The review of systems, an important component of the medical interview, also helps clinicians identify health issues not yet diagnosed but potentially related to the current or future complaints [5]. In a landmark study evaluating the relative importance of the medical history, the physical exam and diagnostic tests, physicians were able to predict accurately diagnosis in 66 of the 80 patients only after taking the medication history [7, 8].

A thorough physical exam starts with observing the patient for general appearance, symmetry, posture and nutritional status which is often reflective of physical and psychological health and disease [5]. The clinician then proceeds to visual inspection of exposed and non-exposed skin, nail and hair, palpation and percussion of body surfaces and auscultation of appropriate organs [5]. Clinical exam can often identify a pivotal clue which narrows down differential diagnoses, help select appropriate tests, and expedite accurate diagnosis without burdening patients with costly, unnecessary diagnostics [6, 7]. In an observational study, Reily et al. Reported that a skilled physical exam offered a critical clue in 26% of patients which changed the diagnosis the medical diagnosis [9]. Although the scope of practice in dentistry differs from medicine, diagnostic approach is essentially the same. Dentists are skilled at taking histories, performing focused physical exams and chairside diagnostic tests when providing dental care. Since the relationship between oral and systemic health is reciprocal and multi-faceted, a holistic approach to patient assessment can also guide dental providers differentiate between oral abnormalities of local and

systemic origin and decide on appropriate management. Recognition of an occult systemic pathosis by an astute oral physician could expedite diagnosis, reduce suffering and help improve medical outcomes. We report a patient in whom the onset of extra and intraoral purpuras raised the suspicion of a systemic disease and prompted medical referral. Unfortunately; however, the patient did not survive.

2. Case Report

A 93-year-old male presented to his private dentist reporting two-day onset of asymptomatic oral lesions which he attributed to traumatic biting while eating. He denied other jaw or facial trauma. The patient's past medical history was significant for hypertension, diabetes, rheumatoid arthritis, thyroid disease, Coronary artery disease, cardiac stent placement and distant prostate cancer successfully treated with radiation. His medications included Glipizide, Atenolol, Clopidogrel, and Aspirin. He was allergic to sulfa drugs. He reported his last medical visit was three months prior to this presentation. Focused review of systems was positive for recent onset of multiple cutaneous and conjunctival discolorations. Extraoral exam revealed scleral hemorrhage in the left eye (Figure 1) and multiple hematomas affecting his arms, legs and upper lip. The patient related his skin bruises to everyday trauma and old age. He had seen an eye specialist regarding the conjunctival bleeding and been reassured it is likely related to a broken blood vessel which is more frequent in the elderly particularly in the context of therapy with antiplatelet agents. Noted intraorally were ecchymosis involving the floor of the mouth, tongue, labial and buccal mucosa (Figure 2). Focal areas of gingival oozing were also present. Radiographic exam was non-contributory.

Clinical impression was that mucocutaneous findings may be a manifestation of an underlying coagulopathy

or a hematological disorder. The patient was advised to rinse with chilled saline to reduce gingival oozing and referred to his primary doctor for immediate evaluation and blood work. While awaiting the result of work up, the patient developed intracranial hemorrhage and expired shortly after. Although a definitive diagnosis remains undetermined, blood work revealed profound thrombocytopenia (platelet count=7000 cells/mm³) - a finding consistent with the patient's clinical presentation.

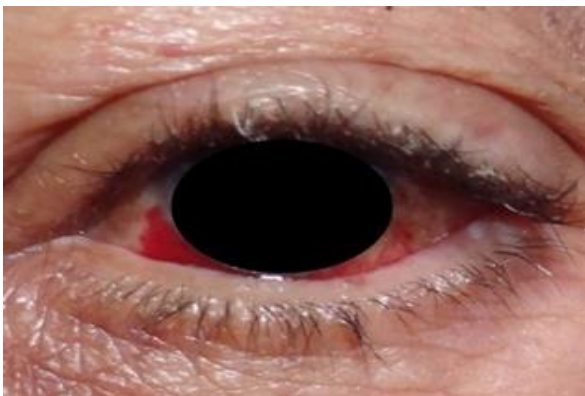


Figure 1: Clinical photo of the patient's left eye with subconjunctival hemorrhage.

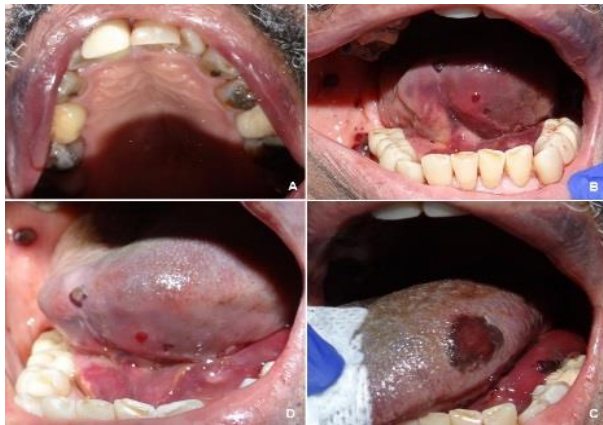

Figure 2: Clinical photo of the oral cavity illustrating multiple ecchymosis affecting the patient's upper vermilion and labial mucosa, ventral tongue, left dorsolateral tongue, floor of mouth and right buccal mucosa.

3. Discussion

A broad spectrum of conditions such as hereditary, coagulopathic, and hematologic disorders may lead to impairment of hemostasis and a variety of manifestations in the orofacial region. Therefore; a working knowledge of pathological basis of various bleeding conditions, together with history, physical and blood work is necessary for determining the underlying etiology. Disorders of hemostasis may present as mucocutaneous pallor, jaundice, cyanosis, petechiae, telangiectasia, spider angiomas, ecchymoses, subconjunctival hemorrhage, epistaxis gingival bleeding, and prolonged bleeding following trauma or surgical procedures [10]. Signs and symptoms of bleeding diathesis in the oral cavity may occur spontaneously, provoked with minimal trauma such as mastication and tooth brushing or follow invasive procedures such as scaling or extractions. In this context, a bleeding episode lasting more than 12 hours, causing soft tissue ecchymosis/hematomas or requiring blood product support leading to an emergency visit or follow up care, may be considered clinically significant [10].

Potential causes of bleeding disorders include vascular anomalies, disorders of platelet number (thrombocytopenia) or function (thrombocytopathy), coagulation defects and fibrinolytic disorders, each of which give rise to specific clinical findings [10]. Vascular disorders such as scurvy or hereditary hemorrhagic telangiectasia are uncommon and are characterized by easy bruising and spontaneous bleeding from small vessels [10, 11]. Platelet disorders may be quantitative (affect the number) or qualitative (affect the function). Thrombocytopenia, a quantitative platelet disorder, may arise from decreased platelet production (e.g. Bone marrow failure, leukemia), or platelet destruction (e.g. idiopathic thrombocytopenia) [10]. Thrombocytopathy (altered platelet function) may

be hereditary (e.g. Von Willebrand disease) [11], drug-induced (e.g. ASA, clopidogrel) or related to a systemic condition (e.g. uremia in renal failure) [10]. Typical manifestations of platelet disorders include superficial petechiae, ecchymosis, spontaneous gingival hemorrhage, epistaxis [10-12] and immediate onset bleeding after surgical procedures [11].

Coagulation disorders may also be familial (e.g. hemophilia) [11], medication-induced (Coumadin, dabigatran, etc.) or related to an underlying liver disease (e.g. cirrhosis). Clinically, coagulation disorders often manifest with late bleeding, large ecchymosis, deep hematomas, and hemarthrosis [10, 11] Fibrinolytic defects could also impair the hemostatic process. Fibrinolytic defects may follow therapeutic interventions with drugs such as streptokinase or conditions causing fibrin depletion such as disseminated intravascular coagulation (DIC) [10]. When indicated, laboratory investigations such as complete blood count (CBC) and coagulation profile (PT, PTT, INR) help screen patients for deficiency of platelets or clotting factors, respectively. In general, in the absence of other complicating factors, routine and incremental oral surgery may be safely performed with platelet count $> 50,000 /\text{mm}^3$, INR < 3.5 or PT/PTT within the normal range. Consultation with the patient's physician is necessary when surgical procedures are planned and the above blood work is outside the acceptable limits.

Proper assessment of patients for bleeding tendencies starts with the medical interview inquiring about the family history, medications, prior experiences with trauma and surgical procedures (Table 1). It is important to question patients specifically about their use of over the counter vitamins and supplements [13]. Depending on the type and dose, these products may impair hemostasis directly or enhance the antiplatelet or anticoagulant action of prescription medications [13]. In

this context, the inspection of oral mucosa, conjunctiva and the exposed skin could provide clues to the presence and nature of an underlying bleeding diathesis and help prioritize the diagnostic work up [11]. Initial recognition of a bleeding diathesis may, in fact, occur in a dental setting [11,12,14] and should prompt referral for medical evaluation.

This patient was an elderly with multiple medical problems and undergoing treatment with two antiplatelet agents. Nevertheless, the rapid and wide spread onset of mucocutaneous findings were disproportionate to possible trauma from daily functions and out of character for bleeding caused by his daily medications raising the suspicion of a faulty internal process. This case exemplifies the holistic approach to assessment of a patient with oral complaints which required interface with a medical counterpart for urgent management. Unfortunately, despite expedited referral to his internist, the serious nature of underlying condition led to the patient's demise before medical evaluation could be completed. The explosion of our understanding of oral-systemic health connection in recent years provides an opportunity for dental professionals to play an even more integral role in holistic patient assessment and care. Dentists are well-positioned to help improve medical outcome by screening patients at risk for many systemic diseases or monitoring those already diagnosed during the dental visit [15]. This fits well with the recent shift in health care paradigm favoring delivery of comprehensive, quality and efficient patient-centered care through inter-professional communication and collaborative practice.

PERTINENT QUESTIONS	RELEVANCE TO HEMOSTASIS
Bleeding episodes following traumatic events or invasive procedures?	<ul style="list-style-type: none"> • Fall, cuts, scratches • Extractions, periodontal procedures
Spontaneous bleeding episodes?	<ul style="list-style-type: none"> • Gingival bleeding in severe thrombocytopenia (< 20,000 cells/mm³), Epistaxis, heavy menstruations, etc.
Location & appearance of bleeding/bruising?	<ul style="list-style-type: none"> • Platelet disorders often manifest with petechia and small superficial cutaneous or mucosal bleeding while coagulation problems often lead to bleeding deep into tissues (large ecchymosis, dissecting hematomas, hemarthrosis)
Timing of bleeding?	<ul style="list-style-type: none"> • Platelet disorders often cause Immediate post-op bleeding; Coagulation disorders often cause delayed post-op bleeding
Family history of bleeding disorders	<ul style="list-style-type: none"> • Identify hereditary bleeding tendencies such as hemophilia or von Willebrand disease)
Social history (alcoholism, IVDA)?	<ul style="list-style-type: none"> • Risk of Hepatitis C-induced liver disease, risk of alcoholic liver disease
Systemic diseases?	<ul style="list-style-type: none"> • Identify bleeding tendencies caused by hepatic, renal or hematological disorders)
Medications?	<ul style="list-style-type: none"> • Anticoagulants (e.g. Coumadin) or antiplatelet agents (eg. Plavix)
Herbal supplements (Ginko biloba, Garlic, etc.)	<ul style="list-style-type: none"> • Supplements can affect platelet function, coumadin metabolism, etc.
Malabsorption or nutritional problems?	<ul style="list-style-type: none"> • Vitamin K or C deficiency may impair hemostasis
Broad spectrum antibiotics	<ul style="list-style-type: none"> • Destroy gut flora producing vitamin K
Current or recent chemotherapy?	<ul style="list-style-type: none"> • bone marrow suppression & thrombocytopenia?

Table 1: A summary of pertinent questions which may help identify potential impairments in hemostasis during the medical interview [10.11.13].

4. Conclusion

A correct clinical impression is integral to initiation of an appropriate management as exemplified in this patient. Dental providers should perform a holistic patient assessment, maintain a high index of suspicion for an occult systemic etiology and expedite referral for medical evaluation when a patient presents with signs and symptoms affecting oral and extra-oral sites. At

times, timely consideration of this possibility could be life-saving.

References

1. Profiles in Science. US National Library of Medicine.
2. 10 Osler-isms to Remember in Your Daily Practice (2014).

3. Centor RM. To be a great physician, you must understand the whole story. *Med Gen Med* 9 (2007): 59.
4. Pitkin RM. Listen to the patient. *BMJ* 316 (1998): 1252.
5. Rakel RE. *Diagnostic Medicine*.
6. Sanders L. *Every Patient Tells a Story*. New York: Broadway Books (2009): 6-91.
7. Muhrer Jill. The importance of the history and physical in diagnosis. *The Nurse Practitioner* 39 (2014): 30-35.
8. Hampton JR, Harrison MJ, Mitchell JR, Prichard JS, Seymour C. Relative contributions of history-taking, physical exam, and lab investigation to diagnosis and management of medical outpatients. *Br Med J* 2 (1975): 486-489.
9. Reilly BM. Physical examination in the care of medical inpatients: an observational study. *Lancet* 362 (2003): 1100-1105
10. Gupta A, Epstein J, Cabay R. Bleeding Disorders of Importance in Dental Care and Related Patient Management. *JCDA* 73 (2007): 77-83.
11. Adeyemo TA, Adeyemo WL, Adediran A, Akinbami AA, Akanmu AS. Orofacial manifestations of hematological disorders: Anemia and hemostatic disorders. *Indian J Dent Res* 22 (2017): 454-61.
12. Martini MZ, Lopez JS Jr, Gendler JL, da Fonseca EV, Soares HA, et al. Idiopathic Thrombocytopenic Purpura Presenting as Post-extraction Hemorrhage. *J Contemp Dent Pac* 8 (2007): 43-49.
13. Wong W, Gabriel A, Maxwell P, and Gupta S. Bleeding Risks of Herbal, Homeopathic, and Dietary Supplements: A Hidden Nightmare for Plastic Surgeons? *Aesthetic Surg Journal* 32 (2012): 332-346.
14. Bal MV, Koyuncuoglu JZ, Saygun I. Immune Thrombocytopenic Purpura Presenting as Unprovoked Gingival Hemorrhage: A Case Report. *The Open Dentistry Journal* 8 (2014): 164-167.
15. Branch-mays GL, Mays KA. Achieving Patient-centered Care through Interprofessional Collaborative Practice.



This article is an open access article distributed under the terms and conditions of the

[Creative Commons Attribution \(CC-BY\) license 4.0](https://creativecommons.org/licenses/by/4.0/)