

Research Article

Role of Ultrasound-Guided Percutaneous Catheter Drainage in the Management of Infected Pancreatic Necrosis

Nam-Hun Jong, Song-Il Rim, Hye-Song Kim*, Chung-Sa Ji, Hak-Chol Ri, Jong-Nam Kang

Department of Gastroenterology, Pyongyang Medical College Hospital of KIM IL SUNG University, Pyongyang, Democratic People's Republic of Korea

***Corresponding author:** Hye-Song Kim, Department of Gastroenterology, Pyongyang Medical College Hospital of KIM IL SUNG University, Pyongyang, Democratic People's Republic of Korea, E-mail: hs.kim@ryongnamsan.edu.kp

Received: 04 October 2019; **Accepted:** 15 October 2019; **Published:** 26 October 2019

Citation: Nam-Hun Jong, Song-Il Rim, Hye-Song Kim, Chung-Sa Ji, Hak-Chol Ri, Jong-Nam Kang. Role of Ultrasound-Guided Percutaneous Catheter Drainage in the Management of Infected Pancreatic Necrosis. Archives of Internal Medicine Research 2 (2019): 061-069.

Abstract

Background: Percutaneous catheter drainage has been widely accepted in infected necrotizing pancreatitis.

Aims: We evaluated clinical safety and efficacy of ultrasound-guided percutaneous catheter drainage in patients with infected pancreatic necrosis.

Subjects: Our prospective study included 44 patients who developed infection of peri/pancreatic necrosis. Of these patients, 25 cases received ultrasound-guided PCD (study group) whereas 21 cases underwent surgery

Intervention: On admission all patients were treated with fluid therapy, nutritional support, antibiotics, gastrointestinal decompression and analgesics. Ultrasound-guided PCD or surgery were performed in patients who suspected infection of necrotic collection. Conversion to surgery were considered in patients who failed to PCD.

Clinical outcomes: primary outcomes were changes in laboratory parameters before and after treatment, recovery days of inflammatory parameters (WBC, CRP). Secondary outcomes were the incidence of complication, mortality and hospital stay.

Results: In the study group PCD period was 30 (median) days (9-91, range). PCD was unsuccessful in 9 (36.0%) patients, who required eventually cross over to necrosectomy. All laboratory parameters (WBC, CRP, serum amylase, blood glucose, serum calcium) were improved after therapy compared to before therapy in both groups ($p < 0.05$). The post treatment comparison showed the level of WBC, CRP, serum amylase and blood glucose in the study group were significantly lower than those in the control group ($p < 0.05$). In PCD group recovery days of WBC, CRP was significantly decreased compared to control group ($p < 0.05$). In study group incidence of new-onset organ failure, intra-abdominal bleeding and incisional hernia significantly reduced than those in the control group ($p < 0.05$). Finally, the mortality rate in the study group was lower than control group and study group had shorter hospital stays compared to control group ($p < 0.05$).

Conclusion: Ultrasound-guided PCD can reduce the need of surgical treatment and step-up approach (PCD followed by surgery) may decrease mortality than primary necrosectomy by minimizing pancreatic injury.

Keywords: Infected pancreatic necrosis; Percutaneous catheter drainage

1. Introduction

Around 20 percent of acute pancreatitis develops necrosis of the pancreas or peripancreatic fat tissue with associated peripancreatic collections [1, 2]. Most of patients with sterile necrosis can generally be managed conservatively and the mortality rate is relatively low (12 percent) [1, 3]. Approximately 30 (range 14-62) percent of pancreatic necrosis, however, develop secondary infection which is associated with ongoing systemic inflammatory response syndrome (SIRS), sepsis and new-onset of organ failure. Thus those patients require aggressive intervention and surgical

necrosectomy by laparotomy has been standardized treatment removing all infected necrosis. However, early necrosectomy carried high morbidity (34-95%) and mortality (11-39%) because inadequate demarcation of necrotic tissue prevents surgeon to remove all debris, which is associated with secondary infection [4-6].

In addition, early surgery may lead to vital tissue injury causing pancreatic juice induced bleeding. In 1998, Freeny and colleagues first introduced CT-guided percutaneous catheter drainage (PCD) in patients with infected pancreatic necrosis [7]. The rationale of this therapy is to temporize sepsis, delay surgical intervention and even reduce the need for surgery by draining liquefied necrotic collection. Since then many clinicians have reported CT or ultrasound-guided PCD in the management of pancreatic complications [8-11]. Ultrasound-guided PCD is a technique without radiation exposure and can be used in the ICU room since it is portable. Moreover, it has the advantage of real-time imaging. Therefore, we aimed to evaluate the safety and efficacy of ultrasound-guided PCD for patients with infected pancreatic necrosis in our tertiary care center.

2. Patients and Method

2.1 Study population

This prospective study included 274 consecutive patients with acute pancreatitis admitted to gastroenterology & abdominal surgery departments, Pyongyang Medical College of KIM IL SUNG University between 2017/1 and 2019/6. Diagnostic criteria for acute pancreatitis is as follows [12].

- Abdominal pain consistent with acute pancreatitis (acute onset of a persistent, severe, epigastric pain often radiating to the back)
- Serum amylase/lipase activity (at least three times greater than the upper limit of normal)
- Characteristic findings of acute pancreatitis on CECT, MRI and transabdominal ultrasound.

- Inclusion criteria
 Infected pancreatic necrosis
- Exclusion criteria
 Sterile pancreatic necrosis, interstitial edematous pancreatitis.

Finally infected necrosis was suspected in 44 patients, of whom 25 cases received ultrasound-guided PCD as a primary treatment (study group). The remaining 21 patients were underwent open necrosectomy initially (control group).

2.2 Treatment

All patients were treated according to the national guideline for acute pancreatitis. Initially, patients received fluid resuscitation, nutritional support, gastrointestinal decompression (placement of nasogastric tube), antibiotics and analgesics at the onset of acute pancreatitis. Infection was suspected in patients who developed clinical deterioration (persistent high fever, increasing CRP, leucocytosis, or presence of peripancreatic gas on CT scans.) in the 2nd week after initial symptoms. In the study group PCD was performed similar to other reports [9, 11, 13]. Firstly, we determined whether access route was feasible using abdominal ultrasonography. When the route was feasible, the freehand technique was used for placement of the catheters into the liquid area of the necrosis under local anesthesia. The catheters were placed using Tandem trocar technique via the transperitoneal or retroperitoneal route avoiding injury to the bowel and other vascular structures. Additionally, the size, number and location of the initial catheters were determined based on the viscosity, quantity and site of collections/necrosis. If the catheter drainage was not sufficient, placement of additional catheters or repositioning, replacing, or upsizing of catheters was conducted by a professional intervention radiologist. Upsizing of catheters were performed using Seldinger

technique. Once drains anchored, irrigation (normal saline 1.5L, 10% povidone-iodine 20mL, 1% hydrogen peroxide 1mL) was performed to evacuate solid necrotic debris or to prevent blockage of the tube at least once a day. A decrease in size of the necrotic collections was evaluated based on daily ultrasound.

In the following situations, catheters could be extracted:

- 1) Catheter output of less than 10 ml per day of nonpurulent fluid for 2 consecutive days (after adequate flushing and ensuring the patency)
- 2) No residual collection on a serial CT scan/ultrasonography; or
- 3) Clinical recovery, i.e., no fever, accepting a normal diet, gaining weight, able to carry out care-self activities.

Crossover to surgical debridement was performed if there was no clinical improvement despite of percutaneous drainage with large-bore catheters. In control group open necrosectomy and a irrigation and drainage of the lesser sac were performed initially.

2.3 Clinical outcomes

Primary outcomes were changes in laboratory parameters (WBC, CRP, serum amylase, blood glucose, serum calcium) before and after therapy, recovery days of inflammatory parameters (WBC, CRP). Secondary outcomes were the incidence of complication, mortality and hospital stay.

2.4 Statistic analysis

Statistical analyses were performed using the Statistical Product and Service Solutions (SPSS Inc., Chicago, IL, version 20.0 for Windows). Descriptive statistics were used including mean \pm SE (normal distribution), median and range (abnormal distribution). Student t test was used for continuous data with normal distribution and Mann–Whitney U test was used for analysis of variable with abnormal distribution. Chi-squared test was performed for categorical variable.

3. Results

3.1 Characteristics of patients

Table 1 shows demographic data, severity index, and presence of organ failure for both groups. There was no significant difference in demographic data, severity and presence of organ failure in the study and control group ($p>0.05$). In study group 18 (72.0%) cases were performed PCD transperitoneally through the gastrocolic ligament alone. Retroperitoneal access through the left lumbar access was used in only 3 (12.0%) patients. Since 4 (16.0%) patients had a large necrotic collection extended down to the lower pole of the left kidney, both transperitoneal and retroperitoneal access were performed simultaneously. Additional PCD was performed in 10 (40.0%) patients because the new liquified collection occurred. PCD period was 30 (median) days (9-91, range) and there was no bowel perforation associated with the procedure. Self-limited bleeding occurred in 2 (8.0%) patients. A median of 2 catheters (range, 1-5) was used per patient, whereas the median size of the catheters was 14F (range, 12-30F). Total 9 (36.0%) patients had crossover to open necrosectomy because of persistent local sepsis (high fever, leucocytosis, increasing CRP, new-onset of organ failure). Our PCD success rate was 64.0% (16 patients).

3.2 Changes in laboratory parameters before and after treatment in both groups

Changes in laboratory parameters before and after therapy in both groups were shown table 2. After

treatment all laboratory parameters were significantly improved compared to before treatment in all groups ($p<0.05$). Additionally, in study group WBC, CRP, serum amylase and blood glucose were significantly reduced compared to control group after treatment ($p<0.05$). However, there was similar in calcium level in both group ($p>0.05$). We also observed recovery days of WBC and CRP (table 3). In PCD group WBC and CRP recovered more quickly than control group ($p<0.05$).

3.3 Incidence of complication, mortality, hospital days in study and control group

Eventually we compared incidence of complication, mortality and hospital days between PCD and surgery group. In study group life threatening complications, including new-onset organ failure, intra-abdominal bleeding were significantly reduced compared to control group ($p<0.05$). The incidence of incisional hernia and diabetes mellitus were lower than control group ($p<0.05$). However the incidence of pancreatic fistula did not show significant difference in both groups ($p>0.05$). In PCD group one patient died of anaphylactic shock while recovering from acute pancreatitis and the other patient died of uncontrolled sepsis. In surgery group 3 patients succumbed to pancreatic juice-induced hemorrhage perhexis whereas 4 patients died of uncontrolled sepsis and organ failure. The mortality rate was lower in the PCD group than in the surgery group and in PCD group the hospital days were significantly reduced ($p<0.05$).

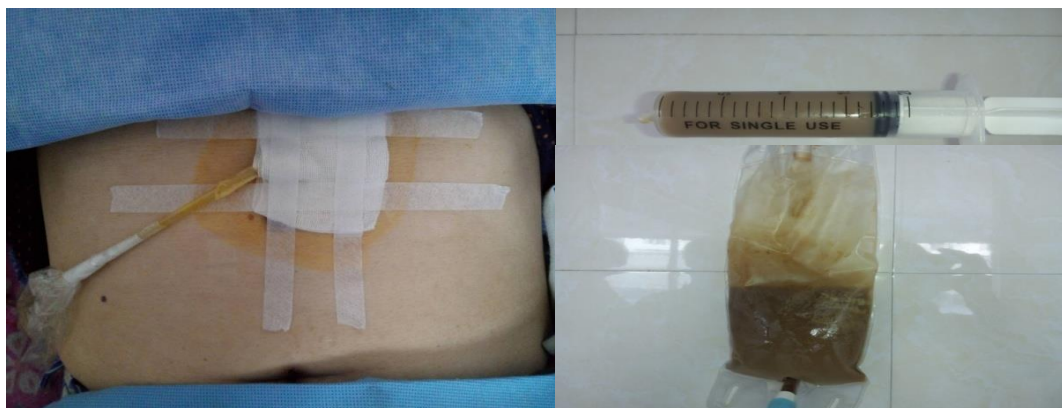Variable		Study group (n=25)	Control group (n=21)
age, X ± SE		44.9 ± 10.1	41.5 ± 11.6
Sex (male), n (%)		15 (60.0)	14 (66.7%)
Etiology n (%)	dietary	6 (24.0)	5 (23.8)
	alcohol abuse	16 (64.0)	14 (66.7)
	gall stone	3 (12.0)	2 (9.5)
CT severity index		8 (6-10)	8 (7-10)

Median (range)		
presence of organ failure before treatment, n (%)	3 (12.0)	2 (14.3)

Table 1: Characteristics of study and control group.

Variable	Study group (n=25)		Control group (n=21)	
	Before therapy	After therapy	Before therapy	After therapy
WBC ($\times 10^9/L$)	15.6 \pm 3.8	9.1 \pm 1.9 ^{a, b}	15.1 \pm 3.5	12.6 \pm 2.9 ^{1a}
CRP (mg/dL)	35.8 \pm 17.2	13.9 \pm 9.5 ^{a, b}	37.3 \pm 15.6	22.7 \pm 12.1 ^a
Serum amylase (U/L)	650.3 \pm 72.1	94.2 \pm 38.5 ^{a, b}	626.9 \pm 85.2	144.5 \pm 57.6 ^a
Blood glucose (mmol/L)	10.7 \pm 2.4	5.5 \pm 0.8 ^{a, b}	11.2 \pm 2.8	8.7 \pm 1.1 ^a
Serum calcium (mg/dL)	7.6 \pm 1.2	9.2 \pm 1.6 ^a	7.9 \pm 1.2	8.8 \pm 2 ^a

a; compared to before treatment, b; compared to control group, $p < 0.05$

Table 2: Laboratory parameters before and after therapy in both group ($X \pm SE$).**Figure 1:** Transperitoneal placement of drain and drained fluid.

Variable	Study group (n=25)	Control group (n=21)
WBC	28.4 \pm 18.7 ^a	39.5 \pm 15.6
CRP	31.2 \pm 16.3 ^a	46.7 \pm 19.4

a; compared to control group, $P < 0.05$

Table 3: Recovery days of WBC and CRP ($X \pm SE$).

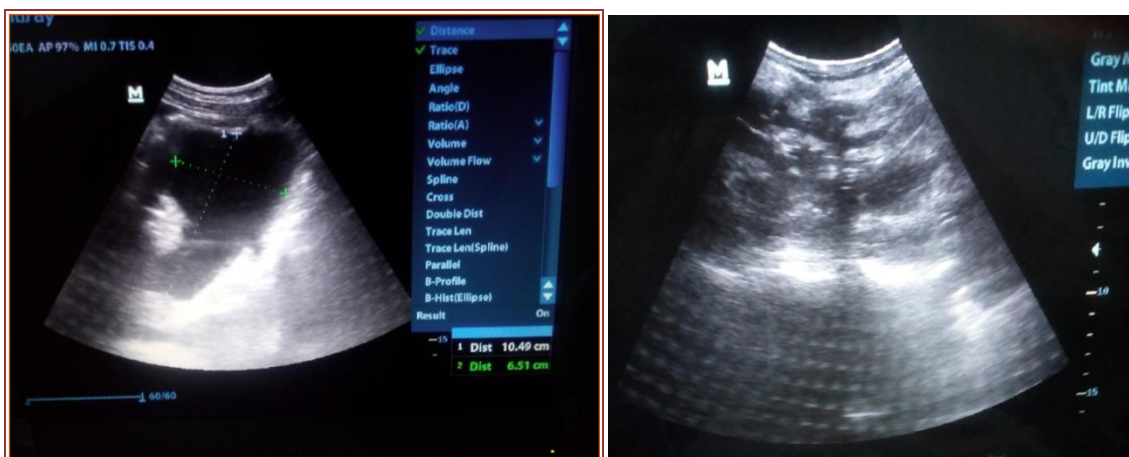


Figure 2: Ultrasound image demonstrating necrotic collection before and after PCD.

(A-extensive acute necrotic collection containing solid debris which extended to the lower pole of left kidney B- the amount of fluid was greatly reduced 2 days after PCD intervention).

Variable	Study group (n=25)	Control group (n=21)
new-onset organ failure, n (%)	3 (12.0) ^a	9 (42.9)
intra-abdominal bleeding, n (%)	2 (8.0) ^a	6 (28.6)
pancreatic fistula, n (%)	7 (28.0)	7 (33.3)
incisional hernia, n (%)	1 (4.0) ^a	5 (23.8)
diabetes mellitus, n (%)	3 (12.0) ^a	6 (28.6)
mortality, n (%)	2 (8.0) ^a	7 (33.3)
hospital days, X±SE	56.3 ± 18.4 ^a	73.9 ± 22.8

a; compared to control group, P<0.05

Table 4: Incidence of complication, mortality, hospital days in both groups.

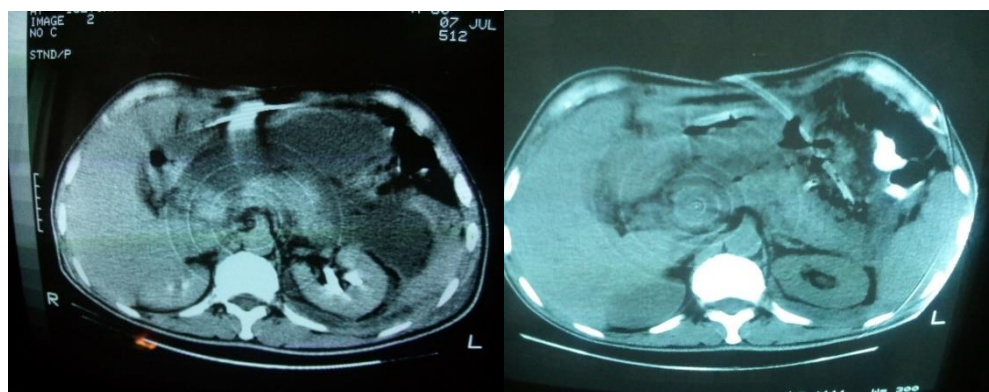


Figure 3: CT scan before and after PCD intervention (A-peripancreatic fluid collection along the whole anterior of pancreas B-most of fluid collection were drained out and small amount of solid debris was left in the pancreatic tail, White arrow shows drain).

4. Discussion

Around one-third of pancreatic necrosis may get infected during the course of acute pancreatitis. This complication should be suspected if a systemic inflammatory response persists for more than 2 weeks after admission and it worsens clinical status leading to sepsis. With the evolution of minimally invasive techniques in recent years, many clinicians have been devoting efforts to the minimally invasive drainage techniques for infected necrotic tissue, such as PCD (CT or ultrasound guided), endoscopic intervention and laparoscopies pancreatic necrosectomy, and so on [7, 14-16]. Our study shows that PCD was successful in 16 patients (64.0%) of the total 25 cases without the need for surgical management. The success rate of percutaneous catheter drainage in infected pancreatic necrosis is relatively varied ranging from 0 to 78 % [17-19]. A systemic review from 11 studies including 384 patients reported surgical necrosectomy could be avoided in 56 % of the patients [8]. In the largest cohort of ultrasound-guided PCD in patients with infected pancreatic necrosis, 58 of 69 patients (84 %) underwent successful percutaneous drainage [9]. Our results and above mentioned literature [9] support that more than 50% of patients with infected necrosis can be treated with PCD with vigorous irrigation. Unlike other study [20] we did not perform Vit. K, FFP and platelet supplementation to treat coagulopathy, because 2 episodes of bleeding associated with PCD technique were self-limited. Thus we consider PCD does not require administration of antithrombotic unless the patient has pre-existing coagulopathy. We also estimated clinical effectiveness of step-up approach (PCD followed by necrosectomy) in the management of infective necrotizing pancreatitis. Post treatment showed significant improvement in WBC, CRP, serum amylase and blood glucose between two groups though all laboratory parameters were significantly improved compared to before treatment in all groups.

Improvement of serum amylase and blood glucose suggests that PCD may reduce injury to the vital tissue and stabilize the pancreas. Recovery days of WBC and CRP were also significantly reduced in the study group. PCD can suppress systemic inflammatory response syndrome by evacuating necrotic collection containing inflammatory cytokines, only via large-bore catheter.

The interestingly incidence of all complications was significantly decreased in the study group except pancreatic fistula. Pancreatic fistula is one of the most complications associated with PCD technique, which closes spontaneously in several months. Today, there is general agreement that surgery in SNP should be performed as late as possible to decrease morbidity and mortality in necrotizing pancreatitis [21]. The third to fourth week after the onset of the disease is agreed as providing optimal operating conditions with well demarcated necrotic tissue present, thus limiting the extent of surgery to pure debridement and to only one single intervention. This approach decreases the risk of bleeding, minimises the surgery related loss of vital tissue, and thus reduces the rate of endocrine and exocrine pancreatic insufficiency. This theory is supported by the fact that incidence of major complications (new-onset organ failure, intraabdominal bleeding, diabetes mellitus, incisional hernia), mortality and hospital days were significantly decreased in PCD group.

5. Conclusion

Ultrasound-guided PCD can reduce the need of surgical treatment and step-up approach (PCD followed by surgery) may decrease mortality than primary necrosectomy by minimizing pancreatic injury.

References

1. Banks PA, Freeman ML. Practice Parameters Committee of the American College of Gastroenterology. Practice guidelines in acute pancreatitis. *Am J Gastroenterol* 101 (2006): 2379-2400.
2. British Society of Gastroenterology. United Kingdom guidelines for the management of acute pancreatitis. *Gut* 42 (1998): S1-S13.
3. Nieuwenhuijs VB, Besselink MG, van Minnen LP, Gooszen HG. Surgical management of acute necrotizing pancreatitis: a 13-year experience and a systematic review. *Scand J Gastroenterol Suppl* 239 (2003): 111-116.
4. Rau B, Bothe A, Beger HG. Surgical treatment of necrotizing pancreatitis by necrosectomy and closed lavage: changing patient characteristics and outcome in a 19-year, single-center series. *Surgery* 138 (2005): 28-39.
5. Rodriguez JR, Razo AO, Targarona J, Thayer SP, Rattner DW, Warshaw AL, et al. Debridement and closed packing for sterile or infected necrotizing pancreatitis: insights into indications and outcomes in 167 patients. *Ann Surg* 247 (2008): 294-299.
6. Tsiotos GG, Luque-de Le ´on E, Sarr MG. Long-term outcome of necrotizing pancreatitis treated by necrosectomy. *Br J Surg* 85 (1998): 1650-1653.
7. Freeny PC, Hauptmann E, Althaus SJ, Traverso LW, Sinanan M. Percutaneous CT-guided catheter drainage of infected acute necrotizing pancreatitis: techniques and results. *AJR Am J Roentgenol* 170 (1998): 969-975.
8. Van Baal MC, van Santvoort HC, Bollen TL, Bakker OJ, Besselink MG, Gooszen HG. Systematic review of percutaneous catheter drainage as primary treatment for necrotizing pancreatitis. *Br J Surg* 98 (2011): 18-27.
9. Zerem E, Imamovic G, Susic A, Haracic B. Step-up approach to infected necrotising pancreatitis: a 20-year experience of percutaneous drainage in a single centre. *Dig Liver Dis* 43 (2011): 478-483.
10. Marek Wroński, Włodzimierz Cebulski, Dominika Karkocha, Maciej Słodkowski, Łukasz Wysocki, Mieczysław Jankowski, et al. Ultrasound-guided percutaneous drainage of infected pancreatic necrosis. *Surg Endosc* 27 (2013): 2841-2848.
11. Ai X, Qian X, Pan W, Xu J, Hu W, Terai T, et al. Ultrasound-guided percutaneous drainage may decrease the mortality of severe acute pancreatitis. *Journal of Gastroenterology* 45 (2010): 77-85.
12. Peter A Banks, Thomas L Bollen, Christos Dervenis, Hein G Gooszen, Colin D Johnson, Michael G Sarr, et al. Classification of acute pancreatitis: 2012—revision of the Atlanta classification and definitions by international consensus. *Gut* 62 (2013) :102-111.
13. Baudin G, Chassang M, Gelsi E, Novellas S, Bernardin G, Hébuterne X, et al. CT-guided percutaneous catheter drainage of acute infectious necrotizing pancreatitis: assessment of effectiveness and safety. *AJR Am J Roentgenol* 199 (2012): 192-199.
14. Besselink MG, van Santvoort HC, Schaapherder AF, van Ramshorst B, van Goor H, Gooszen HG. Feasibility of minimally invasive approaches in patients with infected necrotizing pancreatitis. *Br J Surg* 94 (2007): 604-608.
15. Charnley RM, Lochan R, Gray H, O'Sullivan CB, Scott J, Oppong KE. Endoscopic necrosectomy as primary therapy in the

- management of infected pancreatic necrosis. *Endoscopy* 38 (2006): 925-928.
16. Parekh D. Laparoscopic-assisted pancreatic necrosectomy: A new surgical option for treatment of severe necrotizing pancreatitis. *Arch Surg* 141 (2006): 895-902.
 17. Gambiez LP, Denimal FA, Porte HL, Saudemont A, Chambon JP, Quandalle PA. Retroperitoneal approach and endoscopic management of peripancreatic necrosis collections. *Arch Surg* 133 (1998): 66-72.
 18. Baril NB, Ralls PW, Wren SM, Selby RR, Radin R, Parekh D, et al. Does an infected peripancreatic fluid collection or abscess mandate operation? *Ann Surg* 231 (2000): 361-367.
 19. Van Santvoort HC, Besselink MG, Bakker OJ, Hofker HS, Boermeester MA, Dejong CH, et al. A step-up approach or open necrosectomy for necrotizing pancreatitis. *N Engl J Med* 362 (2010): 1491-1502.
 20. Kamalraj Maiyazhagan, Mohammed Farooq. Percutaneous Catheter Drainage in the Management of Severe Acute Pancreatitis. *IOSR Journal of Dental and Medical Sciences* 16 (2017): 29-37
 21. Uhl W, Warshaw A, Imrie C, Bassi C, McKay CJ, Lankisch PG, et al. "IAP guidelines for the surgical management of acute pancreatitis." *Pancreatology* 2 (2002): 565-573.



This article is an open access article distributed under the terms and conditions of the [Creative Commons Attribution \(CC-BY\) license 4.0](https://creativecommons.org/licenses/by/4.0/)