

Case Report

Successful Thrombolysis after Prolonged Out-Of-Hospital Cardiac Arrest Due to Acute Myocardial Infarction: A Case Report

Mariana Pezzute Lopes MD^{1*}, Vanessa Sanches Corcioli Bellini MD¹, Tarso A. D. Accorsi MD, PhD², Antonio de Santis MD PhD¹, Francisco Monteiro de Almeida Magalhães MD¹, Carlos André Minanni MD¹, Jose Leão de Souza Júnior MD PhD¹

¹Emergency Department, Hospital Israelita Albert Einstein, Sao Paulo, Brazil

²Telemedicine Department, Hospital Israelita Albert Einstein, Sao Paulo, Brazil

***Corresponding Author:** Dr. Mariana Pezzute Lopes, Emergency Department, Hospital Israelita Albert Einstein, Sao Paulo, Brazil, Tel: +55 11 970962729; Fax: +55 11 2151 5420; E-mail: mari.pezzutelopes@gmail.com

Received: 20 July 2020; **Accepted:** 05 August 2020; **Published:** 08 September 2020

Abstract

Maintenance of high-quality cardiopulmonary resuscitation (CPR) in refractory ventricular fibrillation (VF) and attempted treatment of the underline cause is associated with increased survival in prolonged cardiac arrest (CA). Thrombolysis targeting treatment of presumable acute myocardial infarction during CA, although plausible, is not routinely recommended. However, with the increase in technology to aid diagnosis during cardiac arrest, it is possible to more accurately infer patients who can benefit. This paper is a case report of a patient who presented an out-hospital subtle CA attended promptly by an alone rescuer. Due to geographical and communication conditions, the rescue system was not activated and the patient was transferred to the closer emergency department after 30 minutes of collapse by the rescuer's own means. The patient was resuscitated by a complete team in a satellite emergency unit and monitored with hand-free paddles. The rhythm was recurrent VF and there was rigorous CPR. The electrocardiogram filter showed ST-segment elevation in a short moment of sustained sinus rhythm. Intra-arrest thrombolytic therapy was performed after 25 minutes of in-hospital CA and immediate return to spontaneous circulation (ROSC) observed. Patient underwent cardiac catheterization with angioplasty of the anterior descending coronary and complete neurological recovery. This case report aims to demonstrate the possible effectiveness of thrombolysis during prolonged CA when ST-segment elevation myocardial infarction diagnosis is made by

electrocardiogram filter. High-quality CPR and individualization with underlining cause treatment can promote ROSC, neurological recovery and discharge with good quality of life.

Keywords: Cardiac Arrest; Myocardial Infarction; Thrombolytic Therapy; Cardiopulmonary Resuscitation; Electrocardiography

Abbreviations: CA, cardiac arrest; CPR, cardiopulmonary resuscitation; ED, emergency department; STEMI, ST-segment elevation myocardial infarction

1. Introduction

Prolonged cardiac arrest (CA) started out-of-hospital remains a challenge for the rescue team and it is the main cause of interruption of resuscitation efforts [1]. This condition is usually associated with poor clinical prognosis (demonstrated survival around 5%) [2]. Even for in-hospital scenarios, the CA duration has a linear correlation with mortality: when longer than 30 minutes is related to 5.6% of hospital discharge [3]. Some better prognosis in prolonged CA is described in situations like accidental hypothermia and extracorporeal membrane oxygenation cardiopulmonary resuscitation (CPR), but that is barely available [4, 5]. There are no specific recommendations for prolonged CA and adherence to advanced cardiac life support (ACLS) recommendations are considered as survival predictors: early onset CPR, high-quality CPR, early and correct defibrillation, reversal of the underlying cause and proper post-arrest care. There is no evidence that transportation to hospital during CA is associated with longer survival [6].

One of the most common causes of CA worldwide is the ST-segment elevation myocardial infarction (STEMI). The frequency of coronary occlusion in out-of-hospital CA reaches 36% in survivors and 95% in autopsies-based series [7]. The vast majority of STEMI diagnoses are done after the restoration of spontaneous circulation (ROSC), as well as reperfusion therapy recommendations. Thrombolytic therapy is not inferior to angioplasty in improving the hospital discharge and thrombolysis targeting treatment of presumable acute myocardial infarction during CA, although plausible, is not routinely recommended due to the absence of sustained benefit in specific studies [8, 9]. Patient allocation was heterogeneous in previous studies, with different rhythms of CA and no confirmatory STEMI diagnosis during resuscitation.

Currently, it is possible to better select patients for thrombolytic therapy after the STEMI diagnosis through electrocardiogram filters attached to the hands-free pads [10]. This paper is a case report of a successful thrombolysis after prolonged out-of-hospital cardiac arrest due to acute myocardial infarction.

2. Case Description

A 45-year-old male presented an out-of-hospital sudden collapse during sidewalk running. An alone female bystander was loading her car, promptly acted and confirmed CA after documentation of unconsciousness, absence of respiratory movement and central pulse. Despite the central region of a large city (Sao Paulo, Brazil), the street was deserted, there was no request for help and, incredibly, the rescuer did not have a cell phone at that time. A solitary resuscitation with calls for helps out loud with only continuous chest compressions was underway. After several minutes of unresponsive compression, the fatigued rescuer was helped by an adult man that was walking down the street. At this point there was a controversial decision: the rescuer asked him to drag de victim to her car and drive towards the nearest emergency room (satellite unit of Hospital Israelita Albert Einstein) while she maintained chest compressions. The arrival at the emergency room was cinematic and mobilized the entire emergency team available: an emergency cardiologist assumed the leader's role, delegated functions, listened to the rescuer and in-hospital CPR was started after about 30 minutes of collapse. The initial rhythm was obtained by hands-free pads and ventricular fibrillation was ongoing. The first defibrillation was performed immediately and followed by a rigorous CPR process performed according to the norms of ACLS, closed loop communication, using epinephrine, amiodarone, lidocaine and performing recurrent well-indicated defibrillation with 200 joules. Advanced airway (video-guided orotracheal intubation) was obtained after the first circle. There was recurrence of ventricular fibrillation - electrical storm. The electrocardiogram filter (V1 derivation) showed ST-segment elevation during chest compression, in a short moment of sustained sinus rhythm. After 55 minutes of CA, thrombolysis with alteplase was guided by the rescue leader in view of the high probability of STEMI, and the ROSC was obtained in the next cycle, following the initial infusion of thrombolytic agent (15 mg of alteplase) and without recurrence of ventricular arrhythmias. Patient returned to spontaneous circulation with a low blood pressure and without a normal level of consciousness. The electrocardiogram showed extensive anterior STEMI (Figure 1).

Laboratory tests were collected and compatible with a shock clinical condition (Table 1). There was a maintenance of ST-segment elevation, but stability with 0.2 mcg/Kg/min of norepinephrine (heart rate at 84 bpm, blood pressure at 116 × 70 mmHg, oximetry at 95% with inspired fraction of o₂ at 40% and PETCO₂ at 40 mmHg). Mechanical ventilation stayed at minimum parameters (peep 5 cmH₂O, tidal volume in 12 mL/Kg and respiratory frequency of 15 rpm) and sedation was started with midazolam (0.15 mcg/Kg/min) and fentanyl (0.02 mcg/Kg/min) targeting RAAS -4 for secure transport. Point-of-care ultrasound revealed severe left ventricular dysfunction and absence of significant lung congestion or hypovolemia. After 15 minutes of ROSC, the patient was referral by ambulance to hospital central building intervention cardiology department. The transport was performed by 4 rescuers (1 doctor, 2 nurses, 1 technician) and elapsed without any instability. Patient underwent cardiac catheterization with a time of less than 2 hours since he arrived in the emergency unit. A total occlusion of the anterior descending artery in its middle third was identified at the bifurcation with a diagonal branch (Figure 2). The patient underwent angioplasty of the anterior descending artery with pharmacological stent and kissing balloon for diagonal. The patient was referred to the intensive care unit where he evolved with cardiogenic shock, ejection fraction of 19%, need for

vasoactive drugs, but without ventricular assist device. On the second day of hospitalization he started hemodialysis in the context of acute renal failure (Table 1). After 10 days of hospitalization and 2 failures of extubation due to infectious complications he was extubated and remained without any neurological damage, with progressive increase of diuresis and left ventricle ejection fraction of 45%. He was discharged from hospital with rehabilitation and a nephrologist follow-up and after 3 months he could stop hemodialysis sessions. The last visit made by the resuscitation leader is shown in Figure 3.

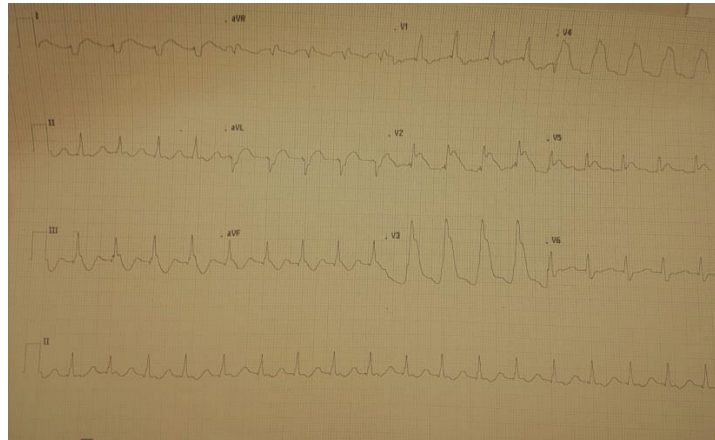


Figure 1: Electrocardiogram immediately after returning to spontaneous circulation showing extensive anterior STEMI.

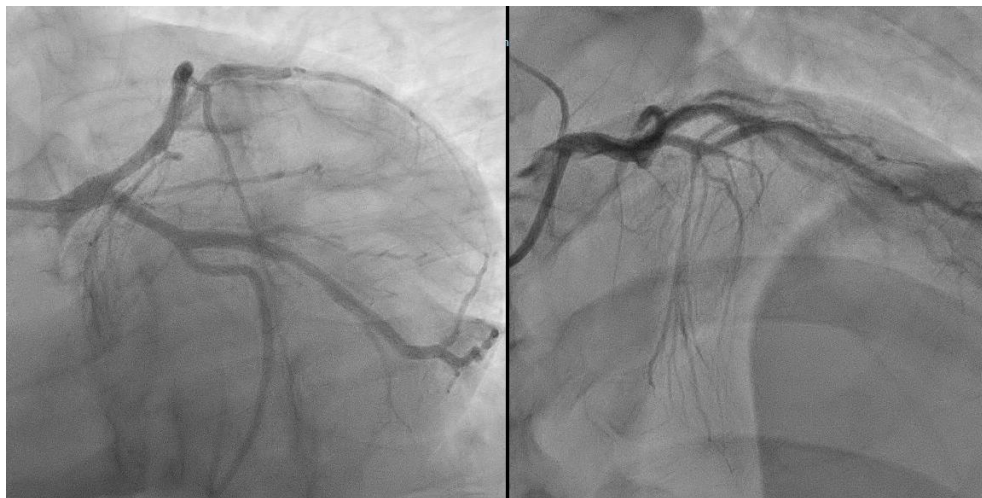

Figure 2: Cardiac catheterization showing total occlusion of the anterior descending artery in its middle third.

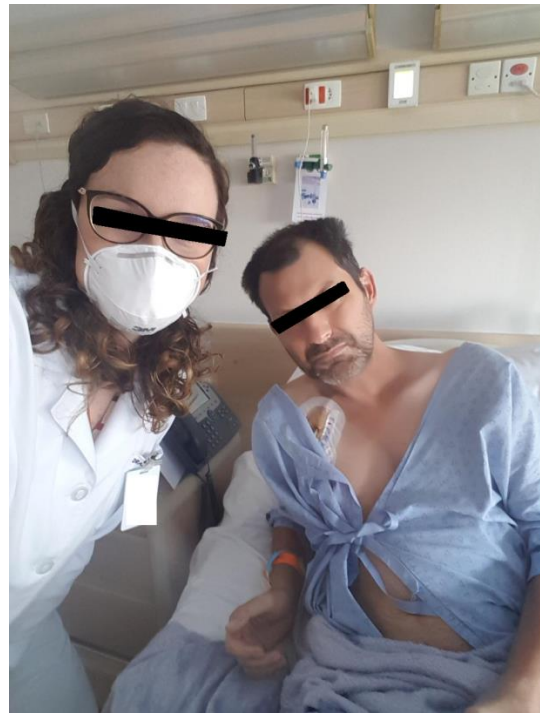

Figure 3: Patient picture taken while he was still in the hospital accompanied by one of the emergency team doctor who was wearing mask due to the 2020 coronavirus pandemic.

Column 1	March/07	March/09	March/30	April/12
Creatinine (mg/dL)	1.91	5.17	8.58	4.88
Urea	58	108	102	114
Potassium (K)	4	4.1	3.9	3.5
Sodium (Na)	138	138	132	136
Troponin	26741	25402		
Hemoglobin	16.6	11.7	8.1	9.7
Hematocrit	46.6	36.5	23.1	28.6
Leukocytes	23780	12570	7070	4320
Platelets	306000	161000	309000	393000
C- Reactive Protein (mg/L)		162	14.3	
pH	7.27	7.32		7.44
Bicarbonate	14.9	15.3		26.3
Lactate	38	46		
Aspartate Transaminase (AST)		148	31	
Alanine Transaminase (ALT)		146	13	

Table 1: Laboratory tests during hospitalization.

3. Discussion

Out-of-hospital CA has a poor survival prognosis compared to in-hospital CA (5% vs. 17%). Thus, the National Association of Emergency Medical Services Physicians suggests that in prolonged out-of-hospital CA with no response after 20 minutes of effective CPR efforts should be discontinued. Regarding morbidity, the probability of hospital discharge with good functionality and without irreversible neurological damage after 15 minutes of CA is only 2%, compared to 75% in patients with short duration CA (less than 15 minutes) [2].

This report begins with an early CA diagnosis in the out-of-hospital environment but followed by a series of dramatic situations that presumably would imply a fatal evolution. The only extra-hospital factor that may have contributed to the surprising outcome was the attempt to continue chest compression. Some cases of prolonged CPR are successful, and possibly the etiology of the CA as well as the individual comorbidities may interfere in the outcome. Extrahospital CA of cardiac cause, especially acute myocardial infarction, when compared to other etiologies, has been associated to better outcomes, even when prolonged, as well as other specific etiologies such as hypothermia, pulmonary embolism and drug overdose [11]. Initial cardiac arrest rhythm also is associated with prognosis and implies markedly different survival rates. A Registry data of 411 hospitals in the National Registry of Cardiopulmonary Resuscitation with a total of 51,919 adult patients with a CA from April 1999 to July 2005 demonstrated that survival to hospital discharge was substantially more likely when the first documented rhythm was shockable rather than non-shockable (adjusted OR 1.68; 95% CI 1.55-1.82). In this case report, patient maintained a shockable rhythm throughout CPR, which encouraged the emergency team to keep efforts besides prolonged CA [12]. Thrombolytic therapy during CA is not recommended by the American Heart Association (AHA) and other guidelines, it is even considered a relative contraindication in view of its risk of bleeding [3]. However, acute myocardial infarction and pulmonary thromboembolism correspond to 70% of CA in an out-of-hospital setting, so the function of thrombolysis in this context remains under debate [13-15].

Beneficial effects of thrombolytic therapy during cardiopulmonary resuscitation were described in several previous reports [14-17]. A retrospective study published by Lederer et al. found a greater chance of ROSC and survival in patients who received alteplase [14]. Additionally, a metaanalysis published in 2006, with a review of 8 papers, found a better rate of ROSC, survival within 24 hours, survival until hospital discharge and absence of irreversible long-term neurological damage in cases undergoing thrombolysis during CA ($p < 0.01$), but with risk of greater bleeding in these cases [20].

Nevertheless, in 2008, a double-blind randomized multicenter trial did not detect an improvement in outcome when, in comparison with placebo, tenecteplase was used during advanced life support for out-of-hospital CA. The primary end point of the study was 30-day survival; the secondary end points were hospital admission, ROSC, 24-hour survival, survival to hospital discharge, and neurologic outcome. The trial was terminated prematurely for futility after enrolling a total of 1050 patients. However, some considerations must be made. First of all, the trial included

patients with any initial electrocardiographic rhythm, and ventricular fibrillation was just 50 percent. Percutaneous coronary intervention was performed in less than 30% of the patients and, due to the limited number of autopsies, it was impossible to confirm the CA causes and circumstances of the underlying disease in all patients. Besides, the interval between collapse and administration of the study drug was much shorter than in many previous reports (18 minutes vs. typically more than 30 minutes) and the surprisingly high overall survival rate (14.7 and 17% in each group) may have contributed to the inability to demonstrate an additional survival advantage for tenecteplase [15]. The patient in this case report does not fit in this trial, which mixed different arrest rhythms, including asystole, different causes of CA (including non-cardiac causes), and with an interval between collapse and administration of the thrombolytic therapy much shorter.

Another retrospective analysis, also published in 2008, in an opposite way, showed excellent survival in patients with myocardial infarction who had cardiac arrest and received thrombolytic therapy. Thrombolysis was initiated during intermittent phases of spontaneous circulation with excellent survival rates and neurological outcome (45% of survivors were discharged with an excellent neurological recovery) (21). Currently it is possible to more accurately infer patients who can benefit from the thrombolytic strategy through the diagnosis of STEMI during CPR using an electrocardiogram filter attached to the hands-free pads, as the patient in the case report [10]. More recent meta-analysis, published in 2019, showed different results compared to old meta-analyses, nine studies were analyzed and no benefit from the point of view of ROSC or survival in 24 hours. Additionally, it again revealed higher risk of bleeding in groups undergoing thrombolysis [14]. Despite the inconsistent evidence, with the need for randomized clinical trials, systemic thrombolysis is still used to achieve ROSC in selected patients with prolonged CA [14].

4. Conclusion

This case report aims to demonstrate the possible effectiveness of thrombolysis therapy during prolonged CA when STEMI diagnosis is made by electrocardiogram filter in transient moments of organized rhythm. Prolonged CA has a poor prognosis, but in cases of high-quality CPR during refractory VF and individualization with targeted underlining cause treatment, it is possible to promote ROSC, neurological recovery and discharge with good quality of life.

Acknowledgement

The authors thank the anonymous first rescuer who attended the patient and transferred him to the closer emergency department by her own means and enabled this successful outcome saving patient's life.

Authors' Contributions

1. Conception, planning, analysis and interpretation of data: Mariana Pezzute Lopes, Vanessa Sanches Corcioli Bellini, Tarso A. D. Accorsi

2. Data collection: Mariana Pezzute Lopes, Vanessa Sanches Corcioli Bellini
3. Writing of the article or its critical intellectual review: Mariana Pezzute Lopes, Vanessa Sanches Corcioli Bellini, Tarso A. D. Accorsi, Carlos André Minanni, Francisco Monteiro de Almeida Magalhães
4. Responsibility for the final approval for publication: Tarso A. D. Accorsi, Antonio de Santis, Jose Leão de Souza Júnior

Disclosures

The authors declare that they have no conflicts of interest related to the present manuscript.

Financial Support

None.

References

1. Bailey ED, Wydro GC, Cone DC. Termination of resuscitation in the prehospital setting for adult patients suffering nontraumatic cardiac arrest. National Association of EMS Physicians Standards and Clinical Practice Committee. *Prehospital Emergency Care* 4 (2000): 190-195.
2. Youness H, Halabi TA, Hussein H, et al. Review and Outcome of Prolonged Cardiopulmonary Resuscitation. *Crit Care Res Pract* (2016): 7384649.
3. Goldberger ZD, Chan PS, Berg RA, et al. Duration of resuscitation efforts and survival after in-hospital cardiac arrest: an observational study. *The Lancet* 380 (2012): 1473-1481.
4. Osborne L, Kamal El-Din AS, Smith JE. Survival after prolonged cardiac arrest and accidental hypothermia. *British Medical Journal* 289 (1984): 881-882.
5. Chiu CW, Yen HH, Chiu CC, et al. Prolonged cardiac arrest: successful resuscitation with extracorporeal membrane oxygenation. *American Journal of Emergency Medicine* 31 (2013): 1627.
6. Neumar RW, Otto CW, Link MS, et al. Adult advanced cardiovascular life support: American Heart Association Guidelines for Cardiopulmonary Resuscitation and Emergency Cardiovascular Care. *Circulation* 122 (2010): S729-S767.
7. Spaulding CM, Joly LM, Rosenberg A, et al. Immediate coronary angiography in survivors of out-of-hospital cardiac arrest. *N Engl J Med* 336 (1997): 1629-1633.
8. Li YQ, Sun SJ, Liu N, et al. Comparing percutaneous coronary intervention and thrombolysis in patients with return of spontaneous circulation after cardiac arrest. *Clinics Sao Paulo* 68 (2013): 523-529.
9. Duchateau FX, Preiss V, Ricard-Hibon A, et al. Out-of-hospital thrombolytic therapy during cardiopulmonary resuscitation in refractory cardiac arrest due to acute myocardial infarction. *European Journal of Emergency Medicine* 8 (2001): 241-243.
10. Aramendi E, Irusta U, Ayala U, et al. Filtering mechanical chest compression artefacts from out-of-hospital cardiac arrest data. *Resuscitation* 98 (2016): 41-47.

11. Myerburg RJ, Conde CA, Sung RJ, et al. Clinical, electrophysiologic and hemodynamic profile of patients resuscitated from prehospital cardiac arrest. *Am J Med* 68 (1980): 568-576.
12. Meaney PA, Nadkarni VM, Kern KB, et al. Rhythms and Outcomes of Adult In-Hospital Cardiac Arrest. *Crit Care Med* 38 (2010): 101-108.
13. Reyner K, Heffner AC, Garvey JL, et al. Successful Use of Intra-Arrest Thrombolysis for Electrical Storm Due to Acute Myocardial Infarction. *Case Reports Am J Emerg Med* 33 (2015): 990.e5-8.
14. Wang Y, Wang M, Ni Y, et al. Can Systemic Thrombolysis Improve Prognosis of Cardiac Arrest Patients During Cardiopulmonary Resuscitation? A Systematic Review and Meta-Analysis. *J Emerg Med* 57 (2019): 478-487.
15. Böttiger BW, Arntz HR, Chamberlain DA, et al. Thrombolysis during Resuscitation for Out-of-Hospital Cardiac Arrest. *N engl j med* 359 (2008): 2651-2662.
16. Lederer W, Lichtenberger C, Pechlaner C, et al. Recombinant tissue plasminogen activator during cardiopulmonary resuscitation in 108 patients with out-of-hospital cardiac arrest. *Resuscitation* 50 (2001): 71-76.
17. Böttiger BW, Bode C, Kern S, et al. Efficacy and safety of thrombolytic therapy after initially unsuccessful cardiopulmonary resuscitation: a prospective clinical trial. *Lancet* 357 (2001): 1583-1585.
18. Fatovich DM, Dobb GJ, Clugston RA. A pilot randomised trial of thrombolysis in cardiac arrest (the TICA trial). *Resuscitation* 61 (2004): 309-313.
19. Bozeman WP, Kleiner DM, Ferguson KL. Empiric tenecteplase is associated with increased return of spontaneous circulation and short term survival in cardiac arrest patients unresponsive to standard interventions. *Resuscitation* 69 (2006): 399-406.
20. Reyner K, Heffner AC, Garvey JL, et al. A meta-analysis of cardiopulmonary resuscitation with and without the administration of thrombolytic agents. *Resuscitation* 70 (2006): 31-36.
21. Arntz HR, Wenzel V, Dissmann R, et al. Out-of-hospital thrombolysis during cardiopulmonary resuscitation in patients with high likelihood of ST-elevation myocardial infarction. *Resuscitation* 76 (2008): 180-184.

Citation: Mariana Pezzute Lopes, Vanessa Sanches Corcioli Bellini, Tarso A. D. Accorsi, Antonio de Santis, Francisco Monteiro de Almeida Magalhães, Carlos André Minanni, Jose Leão de Souza. Successful Thrombolysis after Prolonged Out-Of-Hospital Cardiac Arrest Due to Acute Myocardial Infarction: A Case Report. *Archives of Clinical and Medical Case Reports* 4 (2020): 788-796.



This article is an open access article distributed under the terms and conditions of the [Creative Commons Attribution \(CC-BY\) license 4.0](https://creativecommons.org/licenses/by/4.0/)